

VENTANA®



PATHWAY anti-HER-2/neu (4B5) Rabbit Monoclonal Primary Antibody Interpretation Guide for Biliary Tract Cancer

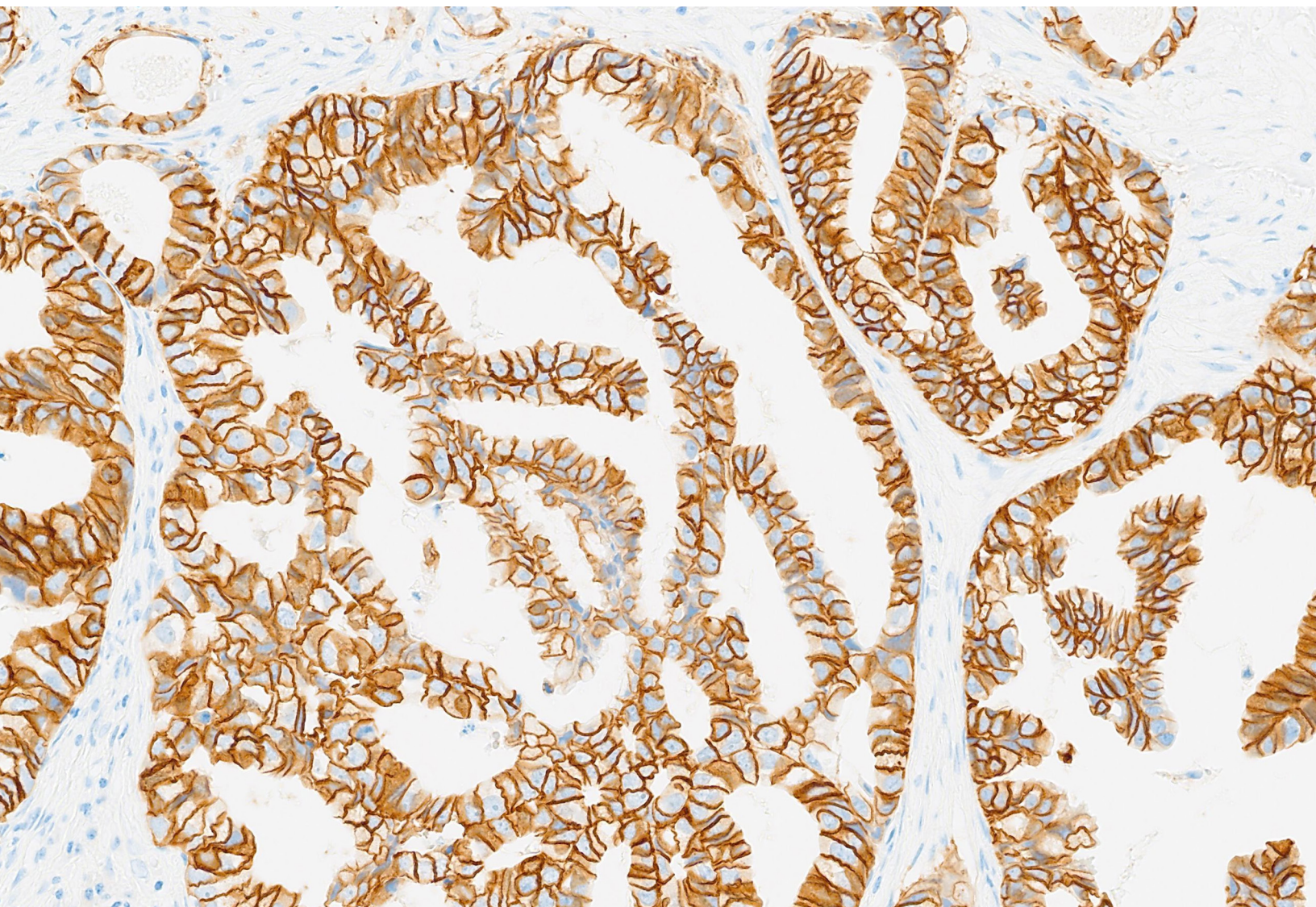


Table of Contents

Introduction	1
Intended Use	3
Intended Use of Product	3
Purpose of Interpretation Guide	3
Clinical Evaluation	4
Staining Characteristics	4
Scoring Algorithm	5
Objective/Magnification Rule	6
Decision Trees	8
Examples of HER2 IHC Images	10
Controls	11
Specimen Workflow	14
BTC Reference Images	17
BTC Resection Reference Images	18
BTC Biopsy Reference Images	28
BTC Borderline Reference Images	37
Challenging Cases	48
Atypical Staining Patterns	48
Staining Artifacts	52
Summary: Important Points to Consider	60
References	61

Introduction

PATHWAY anti-HER-2/neu (4B5) Rabbit Monoclonal Primary Antibody [HER2 (4B5)] is a rabbit monoclonal antibody (clone 4B5) directed against the internal domain of the c-erbB-2 oncoprotein (HER2). The HER2 oncoprotein is a 185-kD transmembrane glycoprotein that is structurally similar to epidermal growth factor receptor (EGFR).¹ The protein is associated with tyrosine kinase activity similar to that of several growth factor receptors and to that of the transforming proteins of the src family. The coding sequence is consistent with an extracellular binding domain. This suggests that HER2 may be involved in signal transduction and stimulation of mitogenic activity.¹

Many tumor types, predominantly malignancies of epithelial origin, demonstrate overexpression of the HER2 protein, amplification of the *HER2* gene, or both.^{2,3}

Biliary tract cancers (BTC), which includes gallbladder adenocarcinoma and cholangiocarcinoma (intra- and extra-hepatic), have been reported to be *HER2* amplified and/or HER2 overexpressed in 5% to 30% of cases.⁴⁻¹³ Gene amplification and protein overexpression were associated with poor prognosis in BTC for overall survival according to several reports.^{8,9}

Intended Use

Intended Use of Product

Refer to the corresponding PATHWAY anti-HER-2/neu (4B5) Rabbit Monoclonal Primary Antibody method sheet (package insert) (P/N 14427, Cat. No. 790-2991) for the detailed intended use of this product.

Purpose of Interpretation Guide

This guide is intended to:

- Provide pathologists with a tool to facilitate the clinical evaluation of formalin-fixed, paraffin-embedded (FFPE) biliary tract cancer (BTC, i.e. gallbladder adenocarcinoma, intrahepatic cholangiocarcinoma, and extrahepatic cholangiocarcinoma) sections stained with PATHWAY anti-HER-2/neu (4B5) Rabbit Monoclonal Primary Antibody [(HER2 (4B5) assay)] in accordance with the proposed product labeling.
- Provide photographic images that illustrate the staining patterns that may result from staining of BTC tissues with the HER2 (4B5) assay.
- Provide example images of challenging cases to provide guidance in their evaluation.
- Provide guidance in using weak HER2-positive invasive breast carcinoma to serve as a tissue control when stained with the HER2 (4B5) assay.
- Provide guidance in using HER-2 4 in 1 Control Slides for use in preliminary validation of instruments used for staining slides with the HER2 (4B5) assay.

Clinical Evaluation

Staining Characteristics

In BTC, staining element(s) (i.e. neoplastic cells) labeled with HER2 (4B5) assay are evaluated for percent of tumor cells staining and staining intensity of the diaminobenzidine (DAB) signal. The VENTANA automated immunostaining procedure causes a brown colored (DAB) reaction product to precipitate at the antigen sites localized by the HER2 (4B5) assay.

Interpretation of the results of any detection system for HER2 must take into consideration the fact that HER2 is expressed in healthy tissue as well as in cancerous tumors, albeit at differing levels and with different patterns of expression.¹⁴ Histological tissue preparations have the advantage of intact tissue morphology to aid in the interpretation of the HER2 positivity of the sample.

The c-erbB-2 (HER2) protein is expressed in the cell membrane of both normal and neoplastic human tissues. Using frozen tissue sections, Press et al. reported weak staining of normal epithelial cells in the gastro-intestinal, respiratory, reproductive, and urinary tract as well as in the skin, breast, and placenta.¹⁵ Intense staining of the cell membrane was found only in the tumor cells of invasive breast carcinoma. Cytoplasmic staining in the absence of membrane staining was not observed by Press et al.¹⁵ It is reported that cytoplasmic staining for HER2 protein is not associated with the presence of detectable HER2 mRNA in breast cancer.¹⁶ Cytoplasmic only staining is not known to be clinically relevant.¹⁶

Evaluating pattern and intensity of staining

HER2 immunohistochemistry has been used for many years in the assessment of breast carcinoma. Many pathologists are therefore well experienced in its assessment in breast carcinoma. The assessment of HER2 in BTC tissues is quite different to that in breast carcinoma. Care should be taken to not adopt a method of assessment in BTC tissues that is influenced by prior experience with HER2 in breast carcinoma.

BTC tissues that are being evaluated for HER2 protein overexpression must meet a threshold criteria for the intensity and pattern of membrane staining (on a scale of 0 to 3+), and for the percent positive tumor cells. Staining must localize to the cell membrane but need not be completely circumferential, as basolateral staining is regularly observed and should be considered for scoring. Staining of the cytoplasm and/or the nucleus may be present, but this staining is not included in the determination of positivity (see **Decision Trees** section). In BTC tissues, the HER2 IHC scoring is dependent on specimen type: resection versus biopsy (see **Table 1**).^{17,18}

This is in contrast to HER2 assessment in breast carcinoma where there is no difference in the criteria between biopsies and resections. Also, in breast carcinoma, complete circumferential membrane staining is important in the scoring of 2+ and 3+ cases, whereas in BTC tissues the membrane staining need not be completely circumferential. Additionally, the assessment of intensity in BTC tissues relies on the use of the microscope objectives as described in the **Objective/Magnification** rule.

The isotype-matched CONFIRM Negative Control Rabbit Ig is used to evaluate the presence of background in test samples and establish a staining intensity baseline.

Non-specific background staining, if present, will have a diffuse appearance. Sporadic light staining of connective tissue may also be observed in tissue sections that are excessively formalin fixed. Intact cells should be used for interpretation of staining results, as necrotic or degenerated cells often stain non-specifically.

Scoring Algorithm

Evaluating HER2 (4B5) assay staining in BTC tissue:

For HER2 (4B5) assay, each case is stained with the PATHWAY anti-HER-2/neu Rabbit Monoclonal Primary Antibody RxDx and a matched negative reagent control (NRC), CONFIRM Negative Control Rabbit Ig. Neoplastic BTC cells labeled with HER2 (4B5) assay are evaluated for presence or absence of the DAB signal. The matched NRC-stained slide is used to assess non-specific background staining and degree of background staining known to occur due to specific tissue elements. It is recommended that a minimum of 100 viable target cells be present for evaluation.

Please note: *ultraView* DAB IHC Detection Kit is the only detection reagent that is recommended for use with the HER2 (4B5) assay.

The scoring algorithm for PATHWAY anti-HER-2/neu Rabbit Monoclonal Primary Antibody RxDx is provided below in **Table 1**. References for each HER2 IHC Score can be seen in Page 6. Representative cases are discussed in the Reference Images section.

Table 1: PATHWAY anti-HER-2/neu Rabbit Monoclonal Primary Antibody Scoring Algorithm for Biliary Tract Cancer

Staining pattern (resection specimen)	Staining pattern (biopsy specimen*)	Score (report to requesting physician)
No reactivity or membranous reactivity in < 10% of tumor cells	<i>No reactivity or membranous reactivity in any tumor cell</i>	0
Faint/barely perceptible membranous reactivity in ≥ 10% of tumor cells; cells are reactive only in part of their membrane	<i>Tumor cell cluster** with a faint/barely perceptible membranous reactivity irrespective of percentage of tumor cells stained</i>	1+
Weak to moderate complete, basolateral or lateral membranous reactivity in ≥ 10% of tumor cells	<i>Tumor cell cluster with a weak to moderate complete, basolateral or lateral membranous reactivity irrespective of percentage of tumor cells stained</i>	2+
Strong complete, basolateral or lateral membranous reactivity in ≥ 10% of tumor cells	<i>Tumor cell cluster with a strong, complete basolateral or lateral membranous reactivity irrespective of percentage of tumor cells stained</i>	3+

*Biopsy specimens include endoscopic, pinch, and needle core

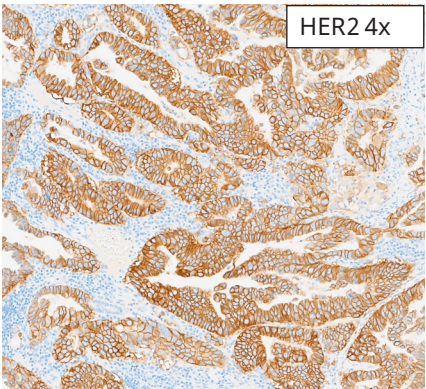
**≥ 5 cohesive cells

Objective/Magnification Rule

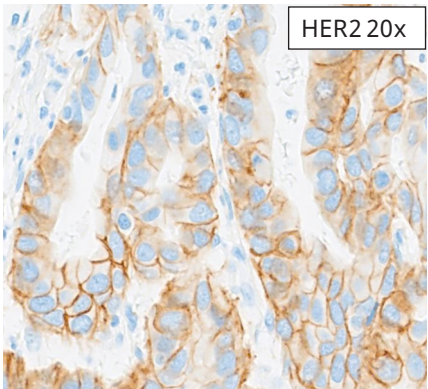
Unlike the assessment of HER2 in breast carcinoma, in BTC tissues the staining intensity is evaluated using the magnification rule. This approach helps to increase the interobserver reproducibility by removing some of the subjectivity associated with intensity assessments.

The intensity assessment is based on the microscope magnification needed to demonstrate distinct (i.e. complete, basolateral or lateral) intercellular membranous staining.

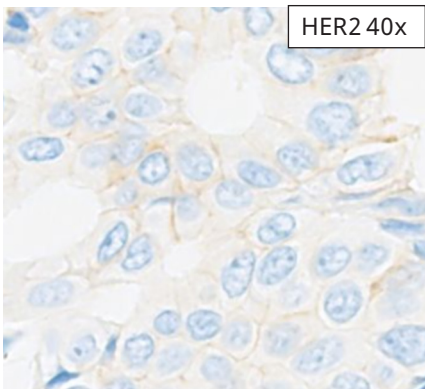
Score	Magnification	Intensity
3+	2x-4x	Strong
2+	10x-20x	Weak to moderate
1+	40x	Faint/barely perceptible
0	40x	Negative



HER2 3+



HER2 2+



HER2 1+

As demonstrated by the magnification rule, the 4x and 20x objectives become very important for distinguishing between HER2 scores. The 4x and 20x objectives should therefore be used judiciously when evaluating cases. It is also important to note that the range of staining intensities that qualify for the 2+ score is quite broad and includes both weak and moderate staining, see pages 22-25 and 32-33.

Implications of Objective/Magnification Rule

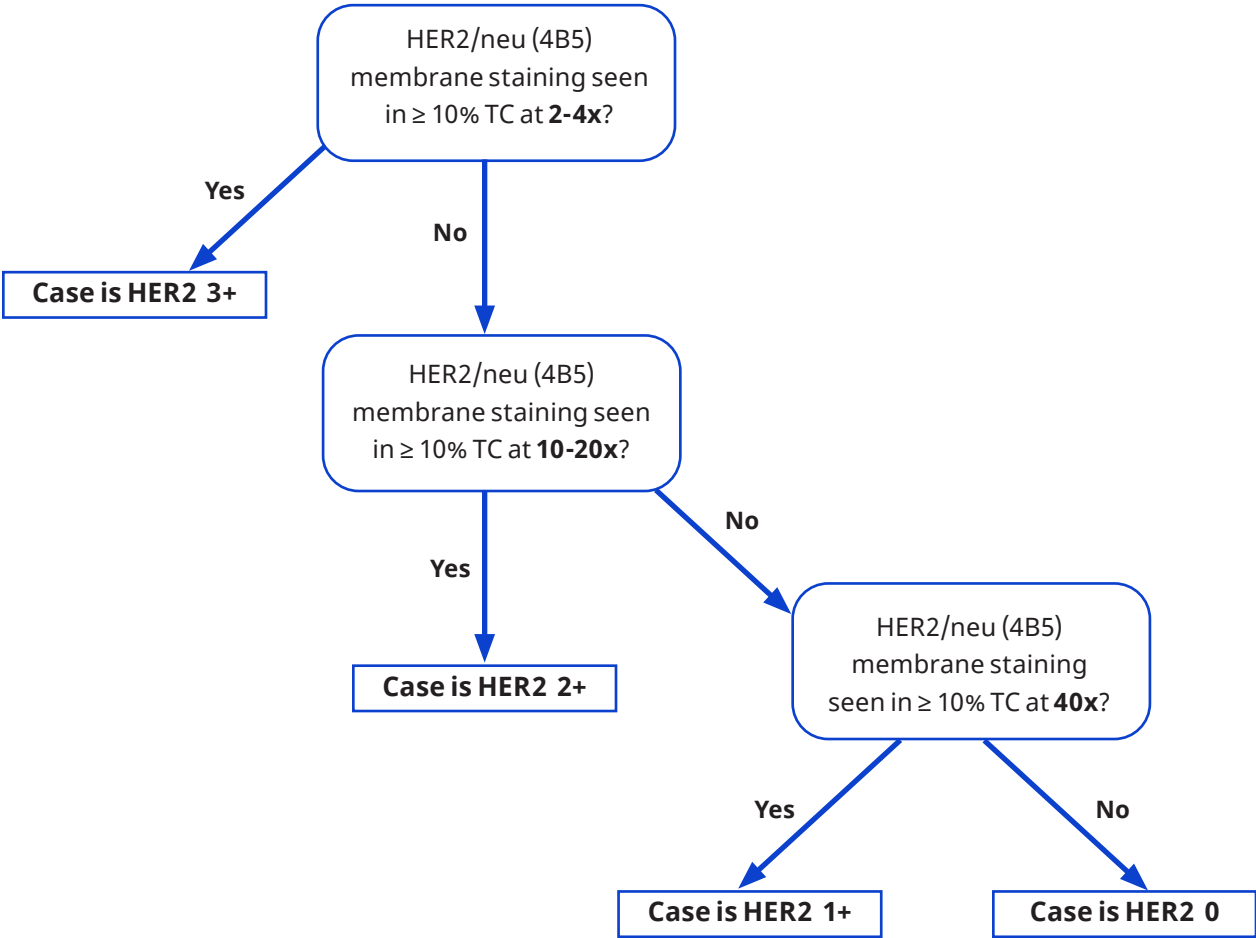
The ability to visualize/detect membrane staining at a given objective is dependent upon intensity of that staining and therefore may be impacted by:

1. Thickness of membrane staining: Thicker membranes are more easily visualized than thinner membranes
2. Morphology of tumor cells (columnar vs. cuboidal vs. polygonal): Latter will have decreased length of lateral membranes, which may be more difficult to detect
3. Concurrent cytoplasmic or cytonuclear staining: Both may obscure membrane staining

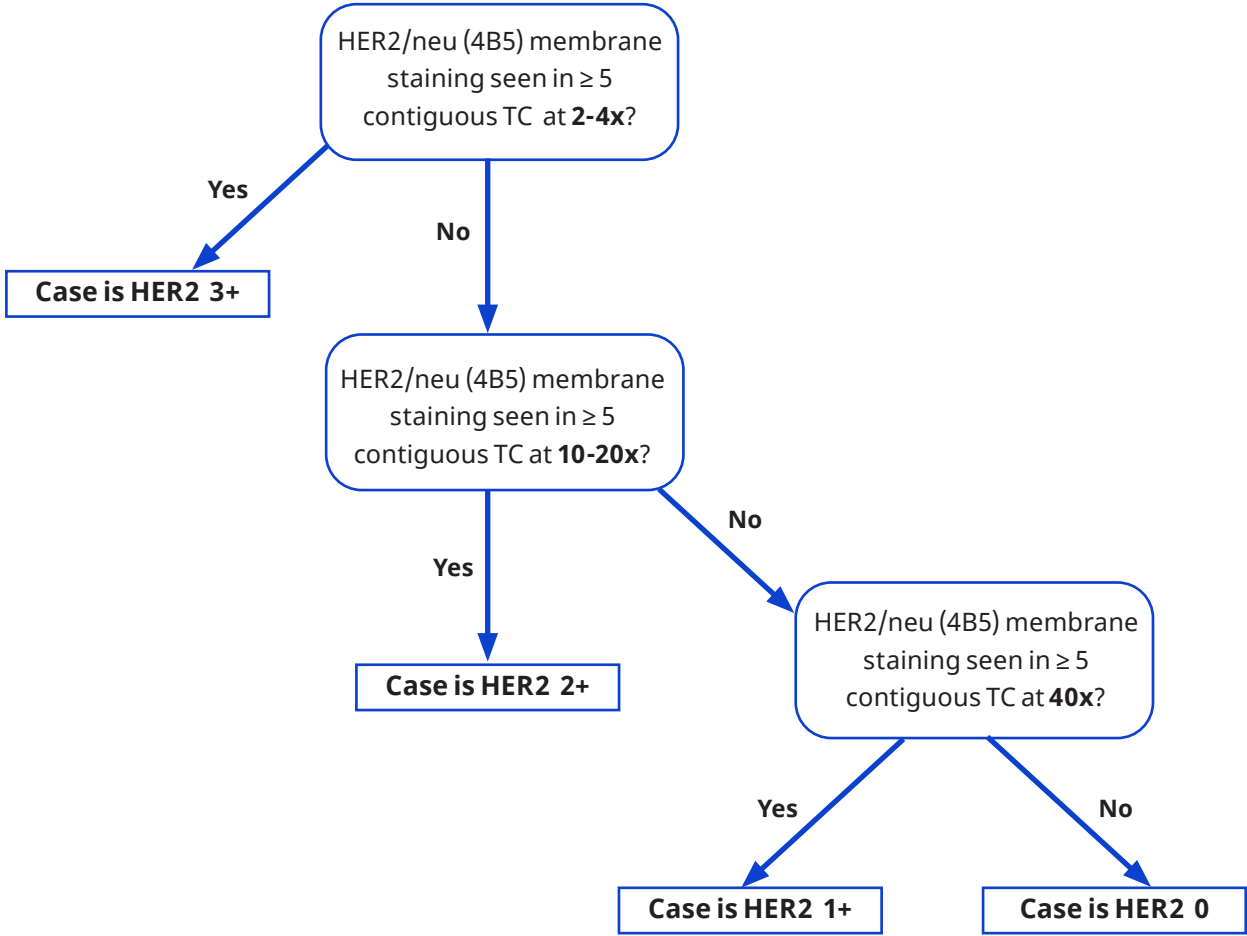
Decision Trees

Tumor cells (TC) in slides stained with PATHWAY anti-HER-2/neu Rabbit Monoclonal Primary Antibody should be evaluated using the approach for resections or biopsies noted in the following figures. Representative cases are discussed in the [Reference Images](#) section.

Study Scoring Workflow for Resections

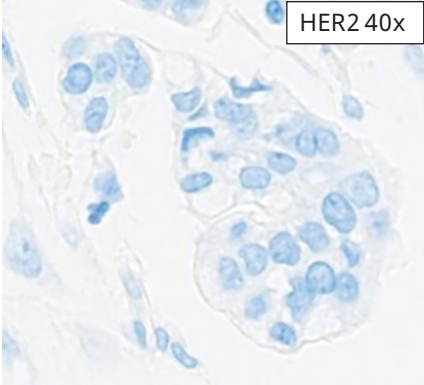


Study Scoring Workflow for Biopsies

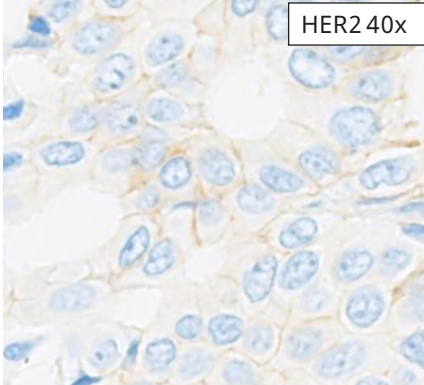


Examples of HER2 IHC Images

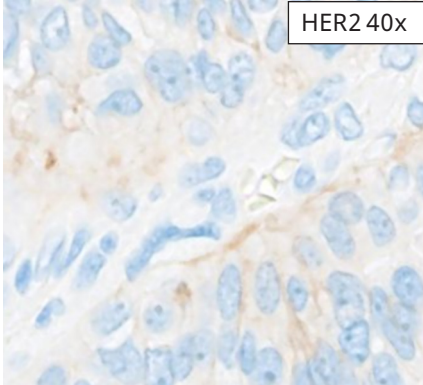
HER2 0 and 1+ IHC Scores



HER2 0

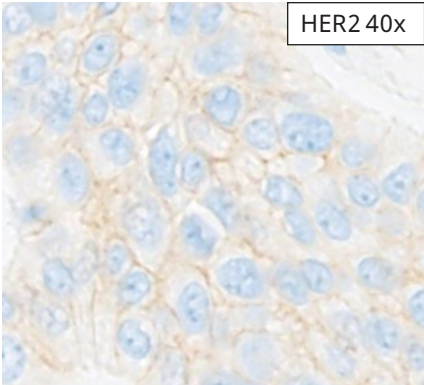


HER2 1+

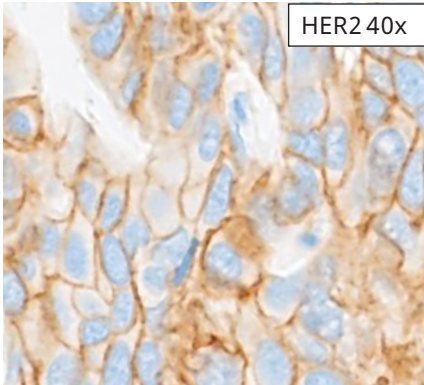


HER2 1+

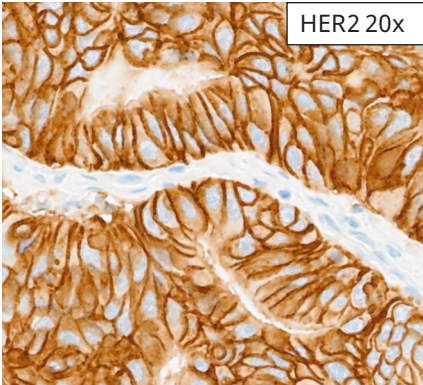
HER2 2+ and 3+ IHC Scores



HER2 2+



HER2 2+



HER2 3+

Controls

Breast Carcinoma

Breast Carcinoma tissues with positive and negative staining elements for HER2 (4B5) assay are recommended for use as run control tissues. HER2 (4B5) assay staining in Breast Carcinoma follows a membranous pattern. Acceptable staining is classified as weak to moderate based on membrane localization, see [Table 2](#) for description. The PATHWAY HER-2 4 in 1 Control Slides can be used as an additional reference.

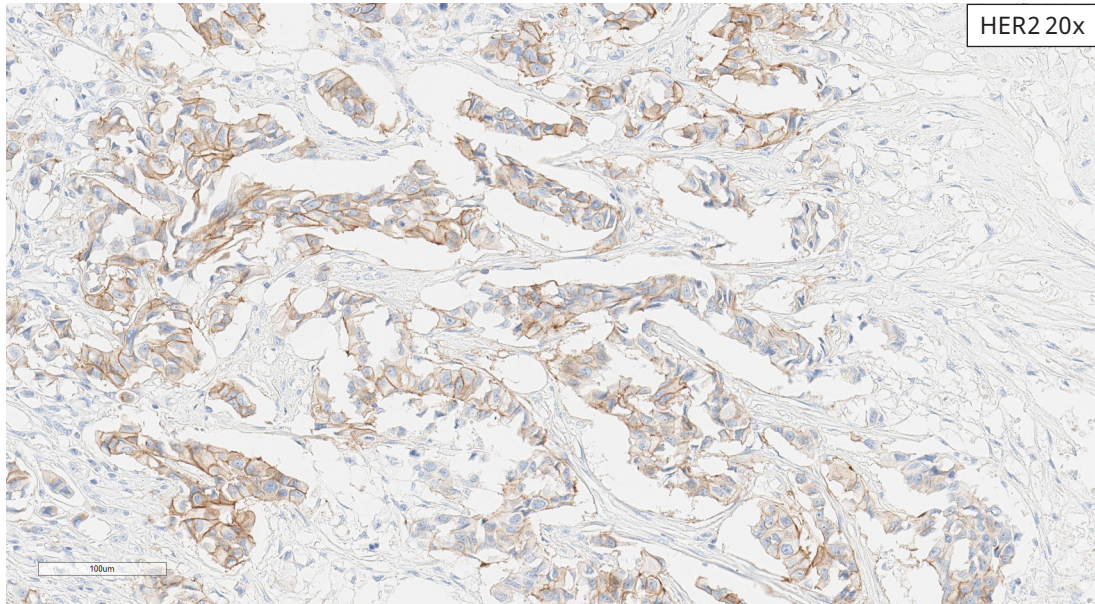
- **Moderate** signal intensity is characterized by rich brown stained membranes that are more easily detected at lower to mid objectives such as 4x or 10x.
- **Weak** signal intensity is characterized by pale tan to light brown membranes that require detection at mid to higher objectives such as 10x or 20x. The weak signal lacks the rich brown color seen in moderate staining intensity; membranes are thinner and are not easily detectable at lower magnification.

A positive control tissue should be a fresh autopsy/ biopsy/surgical specimen that is fixed and processed in the same manner as the patient specimens and should be run for each set of test conditions with every HER2 (4B5) assay performed. This tissue may be used to monitor all steps of specimen processing and staining. A tissue section fixed or processed differently from the test specimen can be used as a control for reagents and staining, but not for fixation or tissue preparation.

Table 2: Acceptance Criteria for HER2/neu (4B5) Staining in Breast Carcinoma Control Tissue

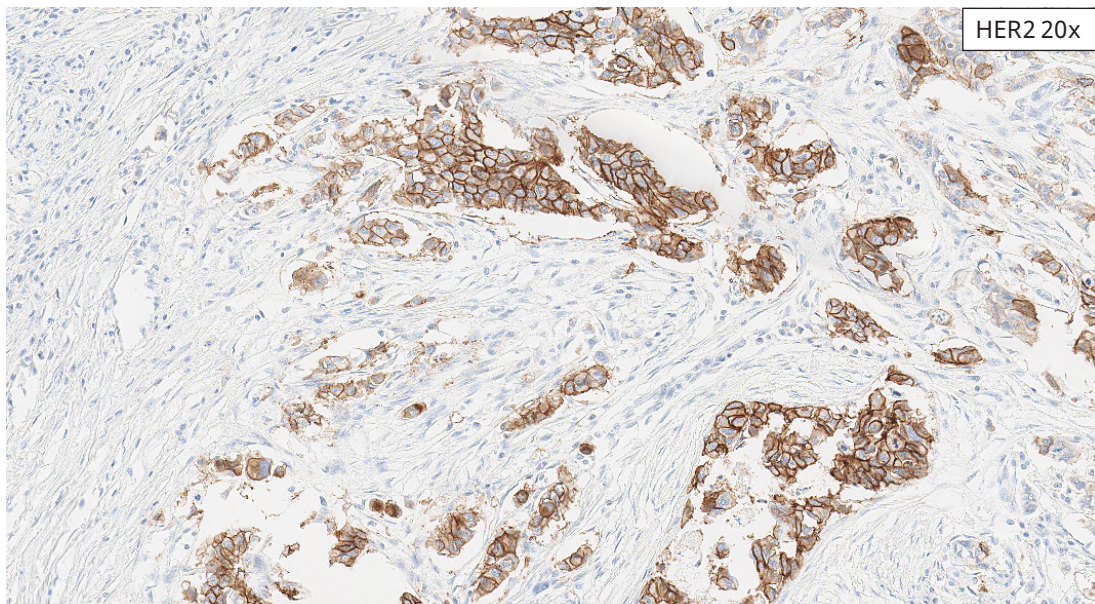
Acceptable	Unacceptable
Positive Tissue Elements: Weak and moderate HER2 membrane staining of tumor cells	Predominance of strong HER2 membrane staining of tumor cells
Negative Tissue Elements: Absence of HER2 staining in stromal tissue; non-staining epithelial cells may also be present.	<ul style="list-style-type: none"> • Predominance of faint HER2 membrane staining of tumor cells or complete absence of HER2 membrane staining of tumor cells • Staining above background in stromal tissue

Acceptable Staining of Breast Carcinoma Control Tissue



An acceptable breast carcinoma control tissue with moderate and weak HER2 membrane staining.

Unacceptable Staining of Breast Carcinoma Control Tissue




An unacceptable breast carcinoma control tissue with primarily strong HER2 staining.

Controls

PATHWAY HER-2 4 in 1 Control Slides may be useful for a preliminary validation of the processing method used for staining slides with HER2 (4B5) assay. When processed

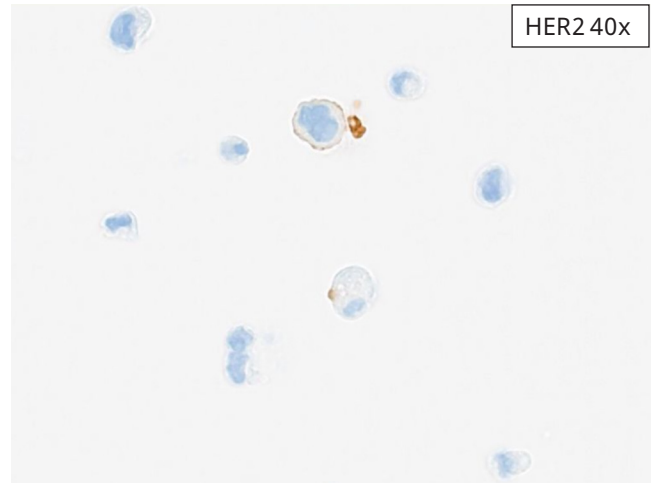
and stained appropriately, the cell lines should stain as described below.

PATHWAY HER-2 4 in 1 Control Slides



HER2 40x

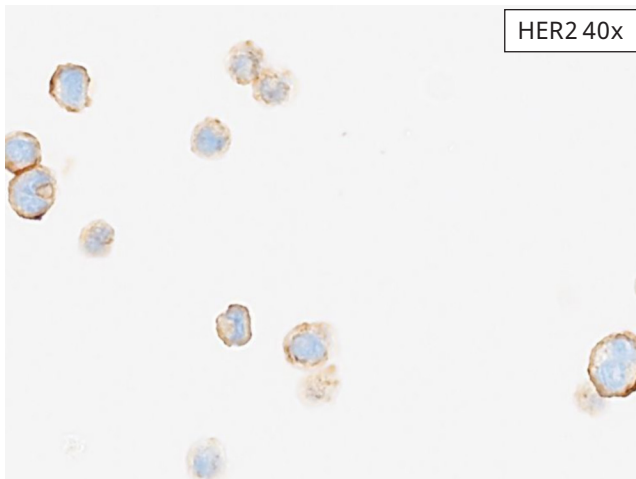(MCF-7 cell line) IHC Score 0: Minimal to no membrane staining.



HER2 40x

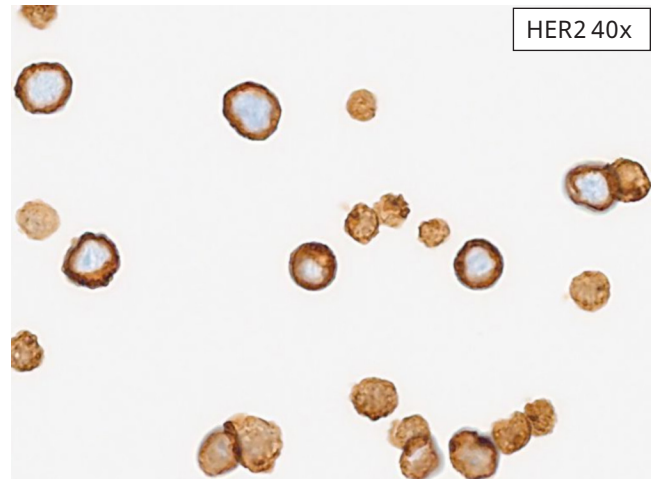(T-47D cell line) IHC Score 1+*: Partial membrane pattern in > 10% of cells.

*Note: because HER2 antigen is not uniformly present on the surface of these cells, not all cross sections will stain identically. When first evaluating this cell line, scan the entire cell field. It may also be necessary to examine it at higher magnification (40x) to pick up the 1+ staining in the scattered cells. When processed appropriately, > 10% of the cells will stain with 1+ intensity.



HER2 40x

(MD-MB-453 cell line) IHC score 2+: Complete "ring" pattern in > 10% of the cells. In contrast to 3+ cases, the staining scored as 2+ has a crisper and more clearly delineated ring, while cases scored as 3+ exhibit a very thick outline (compare to level 3+ cell line control).



HER2 40x

(BT-474 cell line) IHC score 3+: High expression cell line that stains at an intensity level of 3+ with complete "ring" pattern in > 10% of the cells.

Specimen Workflow

Immunohistochemistry (IHC) staining requires three serial sections from each case, one serial tissue section for hematoxylin and eosin (H&E) staining, a second serial tissue section for CONFIRM Negative Control Rabbit Ig staining, and a third serial tissue section for HER2 (4B5) assay staining. If the H&E evaluation indicates that the patient specimen is inadequate, then a new specimen should be obtained and stained with HER2 (4B5) assay.

Positive Control Slides

The positive tissue control must demonstrate appropriate staining for the staining run to be validated. A qualified breast carcinoma tissue will serve as a positive tissue system-level control for each staining run to validate all samples for the respective run. When processed and stained appropriately, the positive tissue control should stain as described in [Table 2](#). If the indicated staining is not evident the staining of the tissues should be repeated.

Negative Reagent Control Slides

A matched NRC slide must be run for every specimen to evaluate non-specific staining and aid in the interpretation of results. Before evaluating a HER2 (4B5) slide, the pathologist must assess the case-matched NRC slide for the presence or absence of specific staining. The corresponding NRC slide must exhibit acceptable staining (i.e., negative for specific staining) in order for the corresponding HER2 (4B5) slide to be considered evaluable. Non-specific staining, if present, will have a diffuse appearance. Sporadic light staining of connective tissue may also be observed in tissue sections that are excessively formalin fixed. Intact cells should be used for interpretation of staining results, as necrotic or degenerated cells often stain non-specifically.

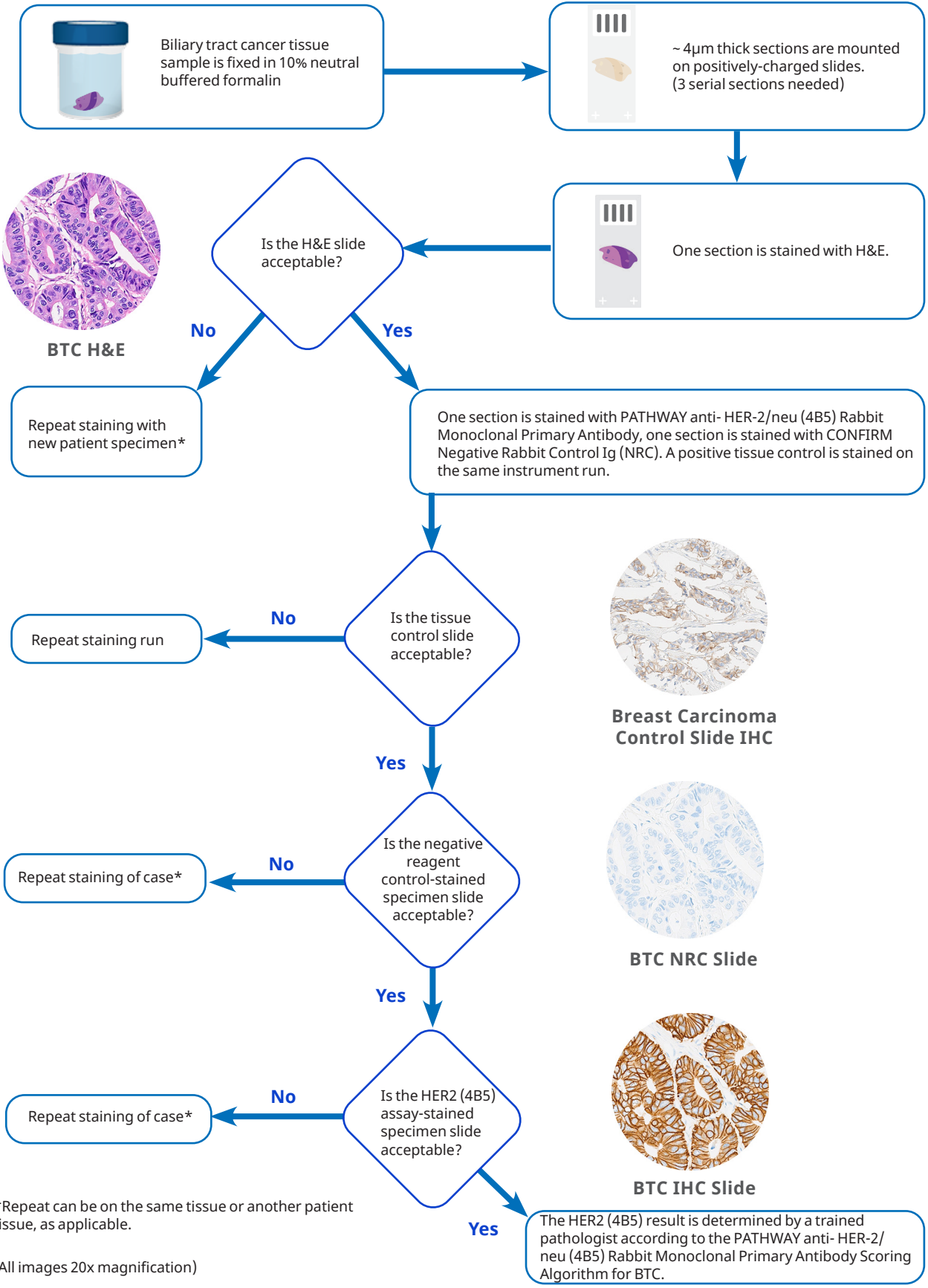
HER2 (4B5) Stained Slides

The tissue morphology and levels of background staining on each HER2 (4B5) slide will be judged as acceptable or unacceptable by the pathologist. Background staining is defined as non-specific staining of the FFPE tissue (as opposed to specific staining of lesional cells in the FFPE tissue).

The pathologist should also review the HER2 (4B5) slide for the overall acceptability of staining. Possible reasons for unacceptable staining include staining artifacts, tissue quality, and tissue wash off. Slides with unacceptable staining performance will not be scored. Repeat testing shall be done with back up slides as available.

A qualified pathologist will evaluate each evaluable HER2 (4B5) slide and assign a HER2 IHC score (0, 1+, 2+, 3+) according to the scoring algorithm defined in [Table 1](#). Intact cells should be used for interpretation of staining results, as necrotic or degenerated cells often stain nonspecifically.

Specimen Flow



BTC Reference Images

Biliary tract cancers (BTC) are a group of indications that are comprised of cholangiocarcinoma (bile duct adenocarcinoma) and gallbladder adenocarcinoma. The following section will show examples of:

Resection Reference Images:

- HER2 IHC Score 0
- HER2 IHC Score 1+
- HER2 IHC Score 2+
- HER2 IHC Score 3+

Biopsy Reference Images:

- HER2 IHC Score 0
- HER2 IHC Score 1+
- HER2 IHC Score 2+
- HER2 IHC Score 3+

Borderline Reference Images:

- HER2 1+, Borderline with 2+
- HER2 2+, Borderline with 1+
- HER2 2+, Borderline with 3+
- HER2 3+, Borderline with 2+
- HER2 3+, Borderline with 0

BTC Resection Reference Images

HER2 IHC Score 0

These cases exhibit either an absence of appreciable HER2 IHC signal of tumor cells, even at higher magnification (40x objective), or membrane staining in < 10% of tumor cells.

START HERE

HER2 (4B5) membrane staining seen in $\geq 10\%$ TC at **2-4x**?

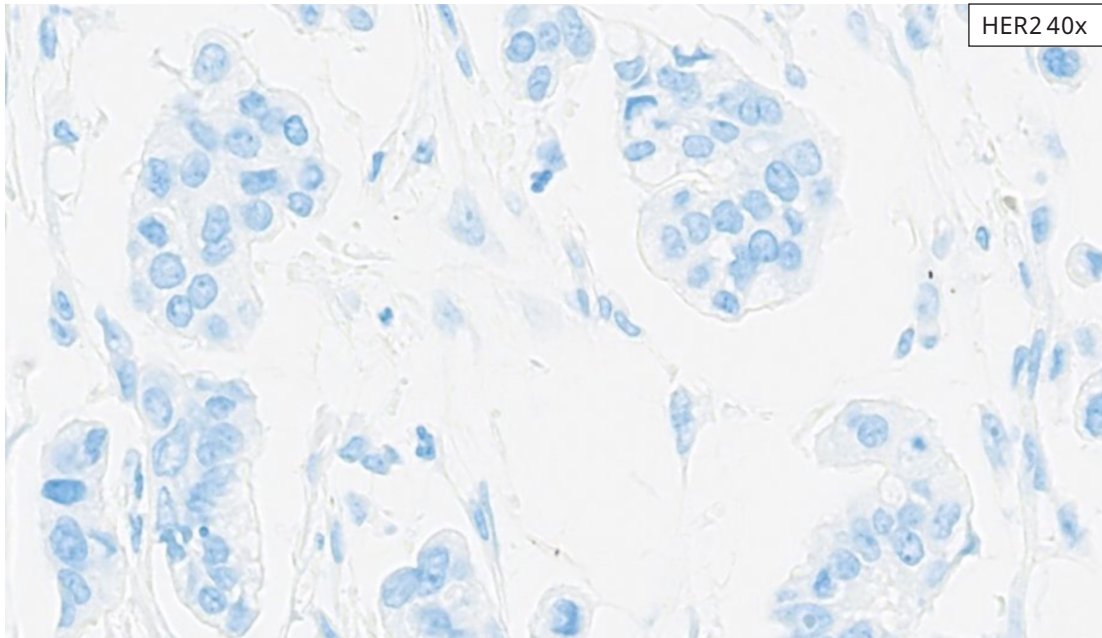
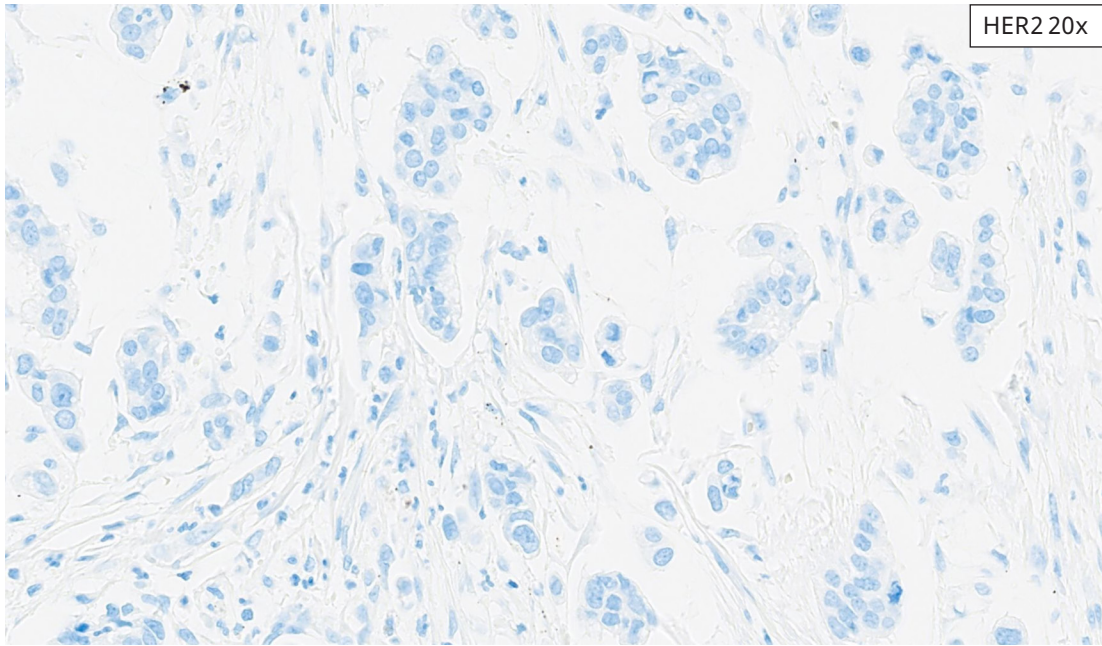
No

Proceed to 10-20x

H&E 20x

HER2 4x

Gallbladder Adenocarcinoma Case: IHC score 0. No membrane staining can be visualized at increasing magnifications: 4x through 40x, consistent with IHC score of 0.



Gallbladder Adenocarcinoma Case: IHC score 0. Membrane staining is clearly absent, even at higher magnifications.

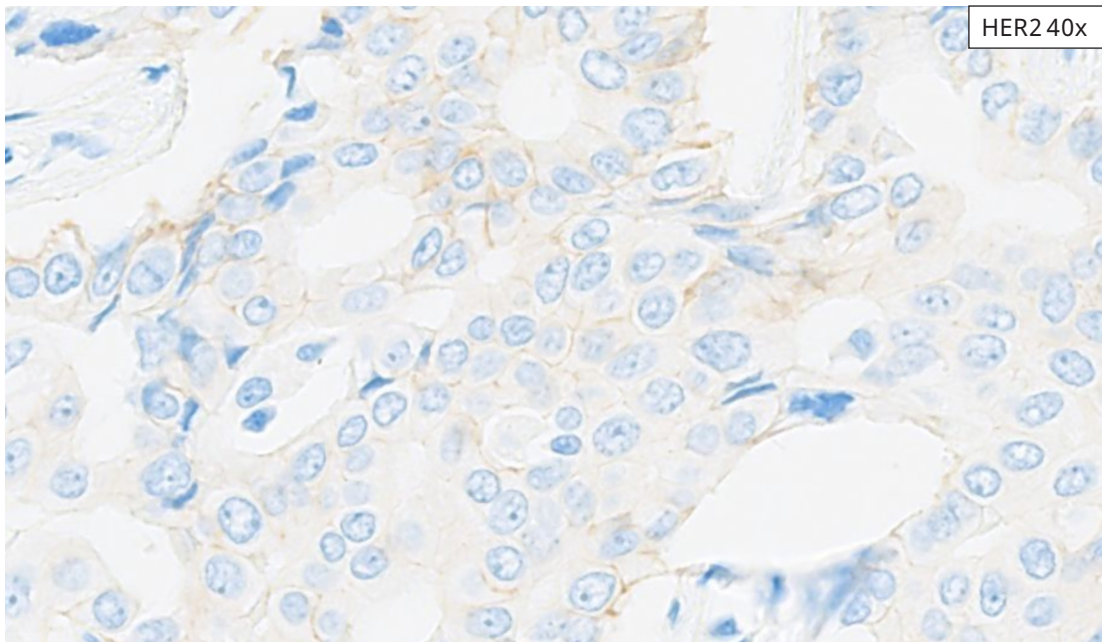
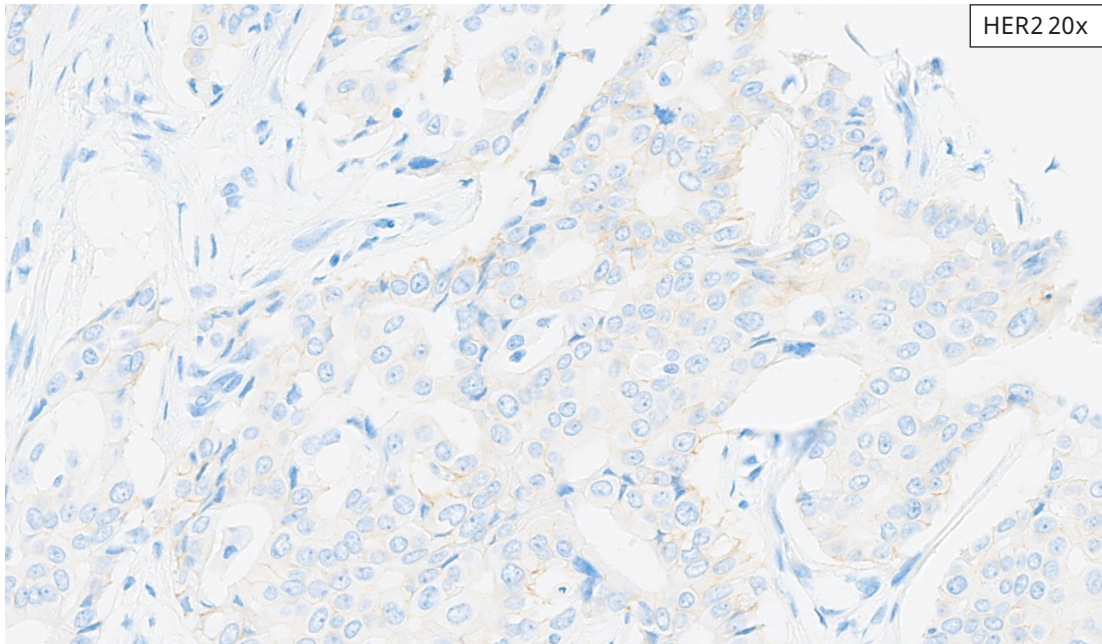
BTC Resection Reference Images

HER2 IHC Score 1+

These cases exhibit a faint/barely perceptible HER2 IHC membranous staining of tumor cells, requiring higher magnification (40x objective) for clear visualization.

The figure consists of a flowchart on the left and two histological images on the right. The flowchart starts with a box labeled "START HERE" with a downward arrow pointing to a rounded rectangle containing the text: "HER2 (4B5) membrane staining seen in $\geq 10\%$ TC at 2-4x?". Below this is a downward arrow labeled "No" pointing to a box labeled "Proceed to 10-20x". To the right of the flowchart are two images. The top image is an H&E stained section at 20x magnification, showing glandular structures of a tumor. The bottom image is an IHC stained section at 4x magnification, showing the same area with very faint, barely perceptible blue membrane staining on the tumor cells. Labels "H&E 20x" and "HER2 4x" are in the top right corners of their respective images.

Gallbladder Adenocarcinoma Case: IHC score 1+. At 4x, no discrete membrane staining is seen, excluding IHC score 3+ for this case.



Gallbladder Adenocarcinoma Case: IHC score 1+. At 20x, membrane staining is seen in $< 10\%$ of tumor cells, excluding IHC score 2+ for this case. At 40x, $\geq 10\%$ of tumor cells are staining, consistent with IHC score 1+.

BTC Resection Reference Images

HER2 IHC Score 2+

These cases exhibit HER2 IHC signal of weak to moderate membranous staining where tumor cell membrane staining can be visualized with 10x and/or 20x objectives.

The figure consists of a flowchart on the left and two microscopy images on the right. The flowchart starts with a box labeled "START HERE" with a downward arrow pointing to a rounded rectangle containing the text: "HER2 (4B5) membrane staining seen in $\geq 10\%$ TC at 2-4x?". Below this is a box labeled "No" with a downward arrow pointing to a box labeled "Proceed to 10-20x". To the right of the flowchart are two images. The top image is an H&E stained section at 20x magnification, showing glandular structures with dark purple nuclei and pink cytoplasm/extracellular matrix. The bottom image is an immunohistochemistry (IHC) section at 4x magnification, showing a light blue background with faint, diffuse staining of the tumor cells.

H&E 20x

HER2 4x

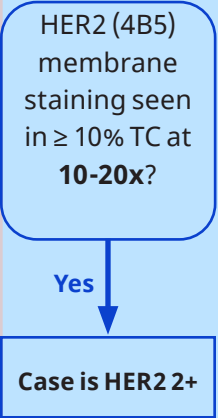
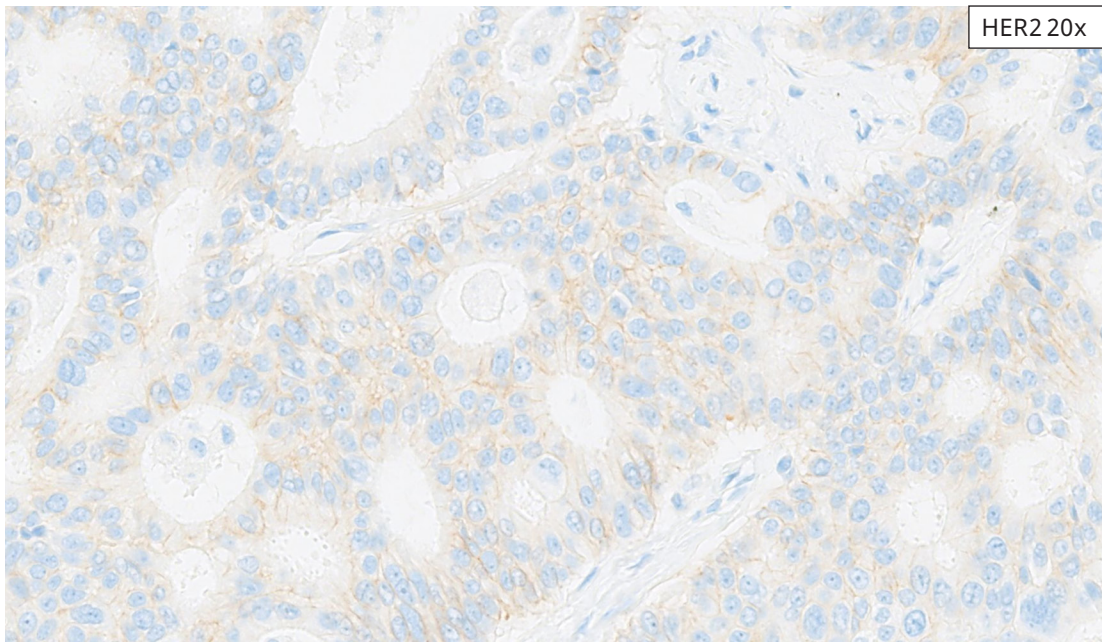
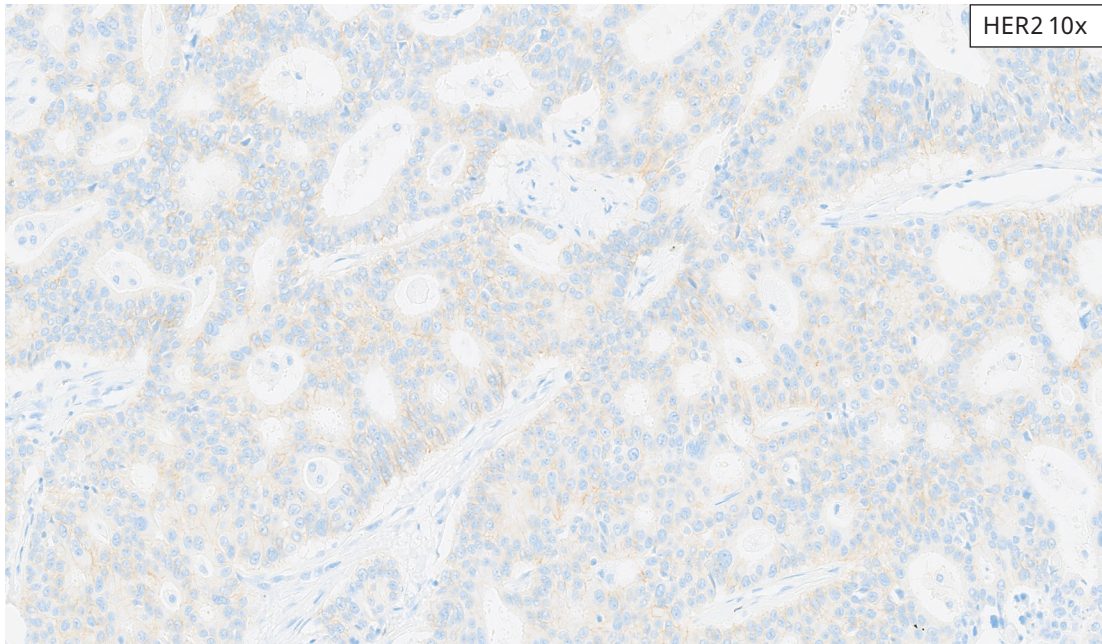
START HERE

HER2 (4B5) membrane staining seen in $\geq 10\%$ TC at 2-4x?

No

Proceed to 10-20x

Cholangiocarcinoma Case: IHC score 2+. At 4x, weak staining is present diffusely, but no discrete membrane staining is seen.

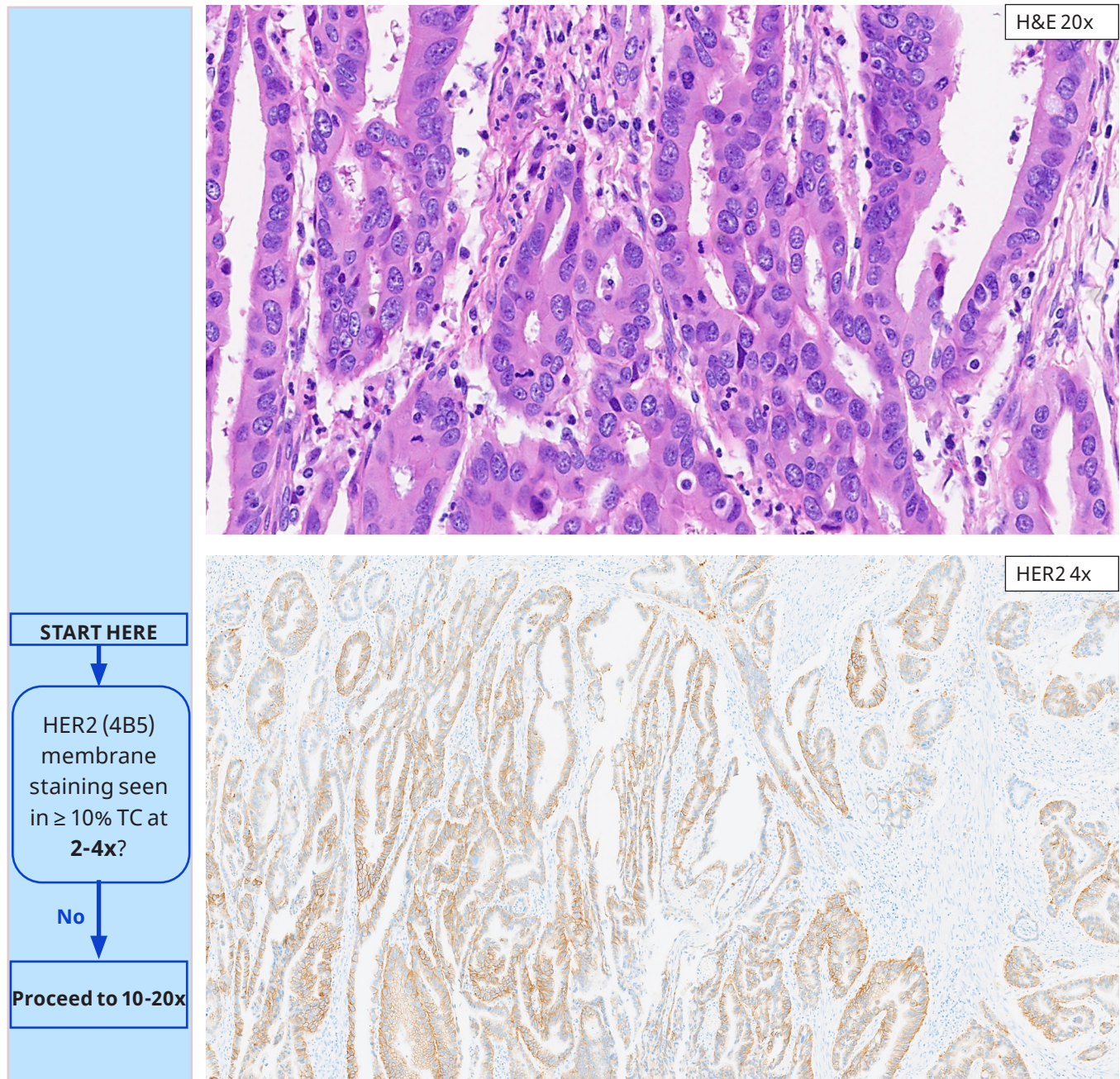


Cholangiocarcinoma Case: IHC score 2+. At 10x, occasional basolateral membranes can be discerned, but in $< 10\%$ of tumor cells. At 20x, however, membrane staining is present in $\geq 10\%$ of tumor cells, consistent with IHC score 2+. Compare this weak 2+ intensity to the moderate 2+ intensity in the next case. Both qualify as 2+ based on the magnification rule.

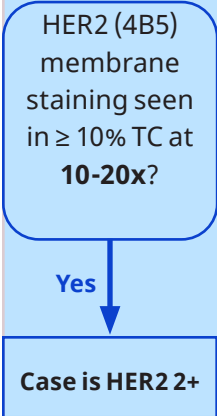
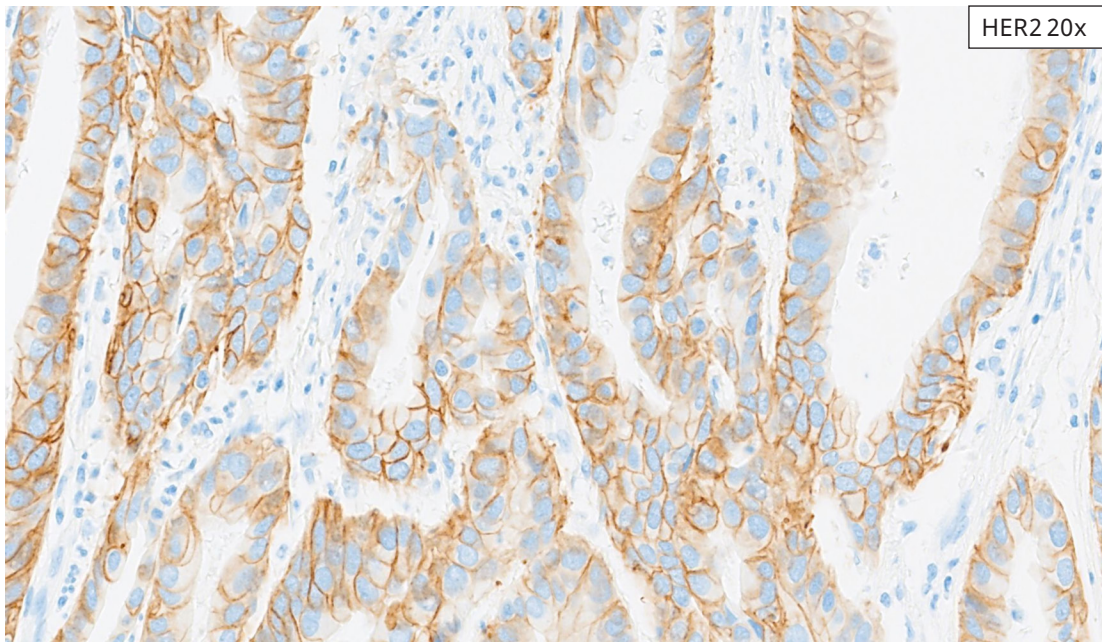
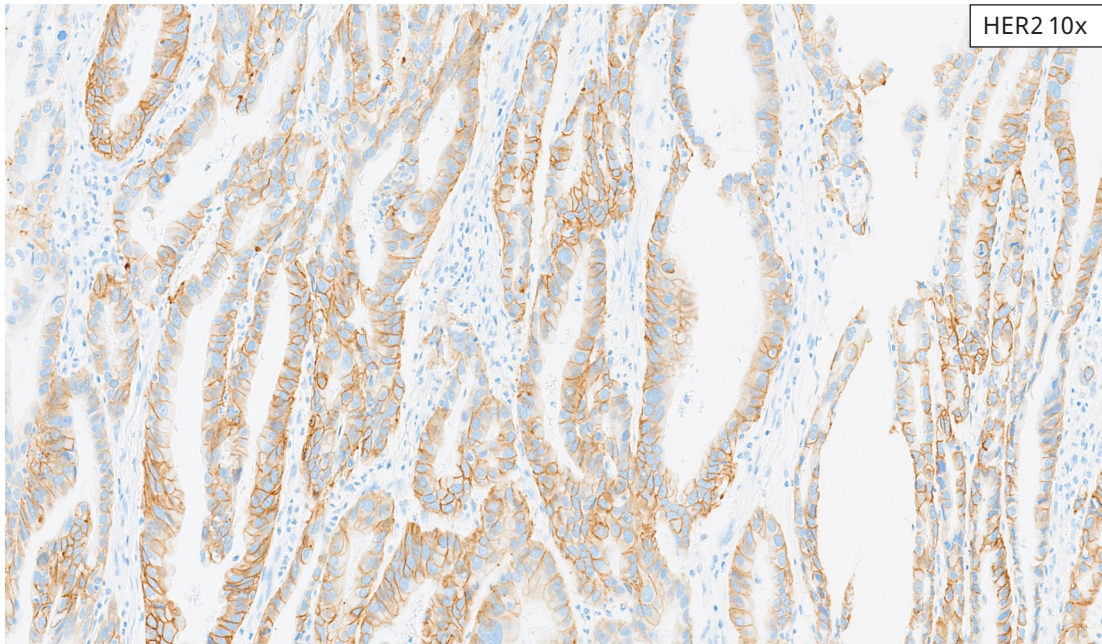
BTC Resection Reference Images

HER2 IHC Score 2+

These cases exhibit HER2 IHC signal of weak to moderate membranous staining where tumor cell membrane staining can be visualized with 10x and/or 20x objectives.



Gallbladder Adenocarcinoma Case: IHC score 2+, higher range. At 4x, membrane staining is seen in $< 10\%$ of tumor cells, excluding IHC score 3+ for this case.

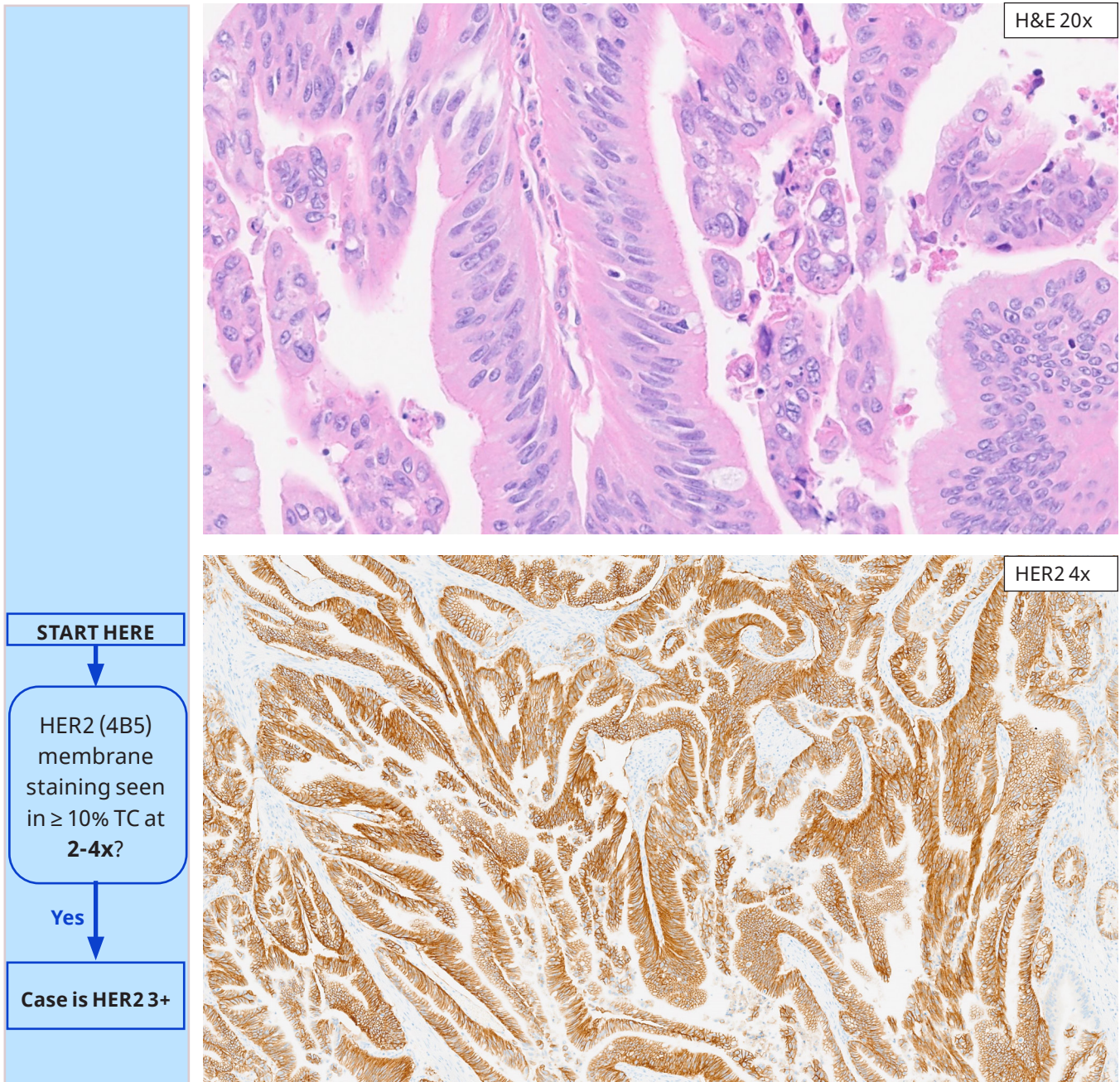


Gallbladder Adenocarcinoma Case: IHC score 2+, higher range. At 10x and at 20x, basolateral staining is readily seen in $\geq 10\%$ of tumor cells, consistent with IHC score 2+.

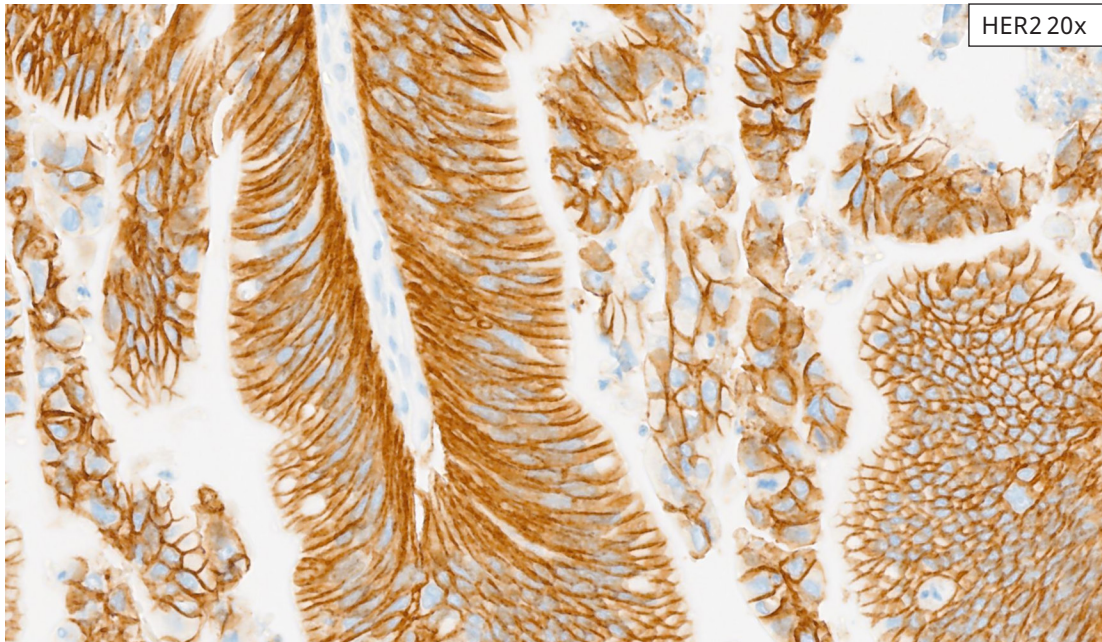
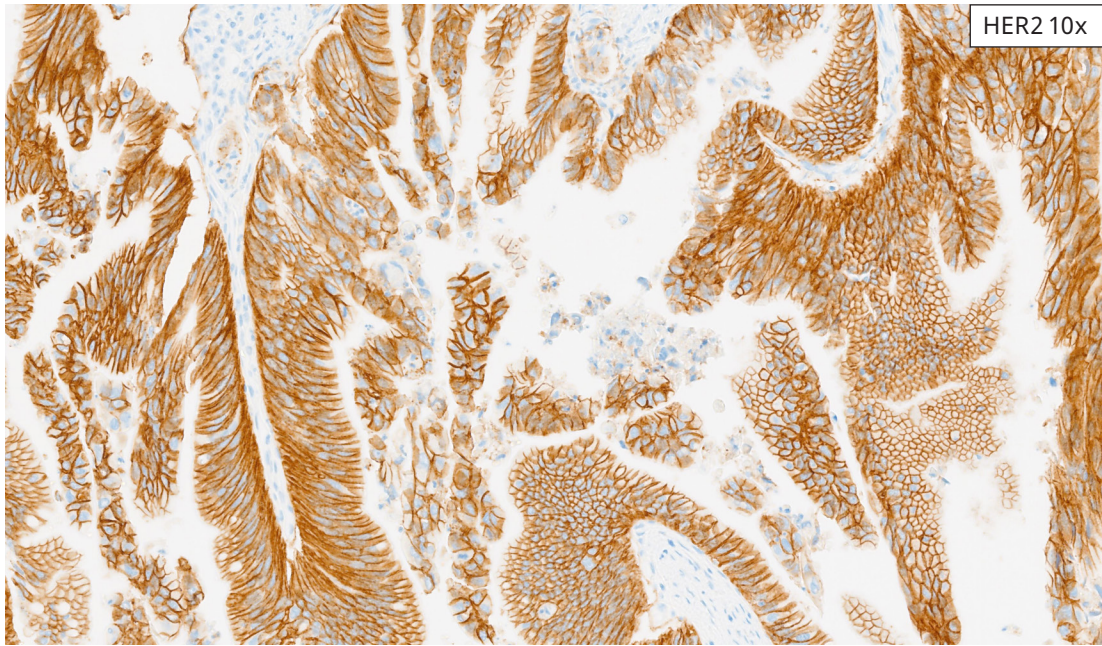
BTC Resection Reference Images

HER2 IHC Score 3+

These cases exhibit HER2 IHC signal of strong membranous staining where tumor cell membrane staining can be visualized with 2x and/or 4x objectives.



Cholangiocarcinoma Case: IHC score 3+. At 4x, membrane staining can be seen in $\geq 95\%$ of tumor cells, consistent with IHC score of 3+.

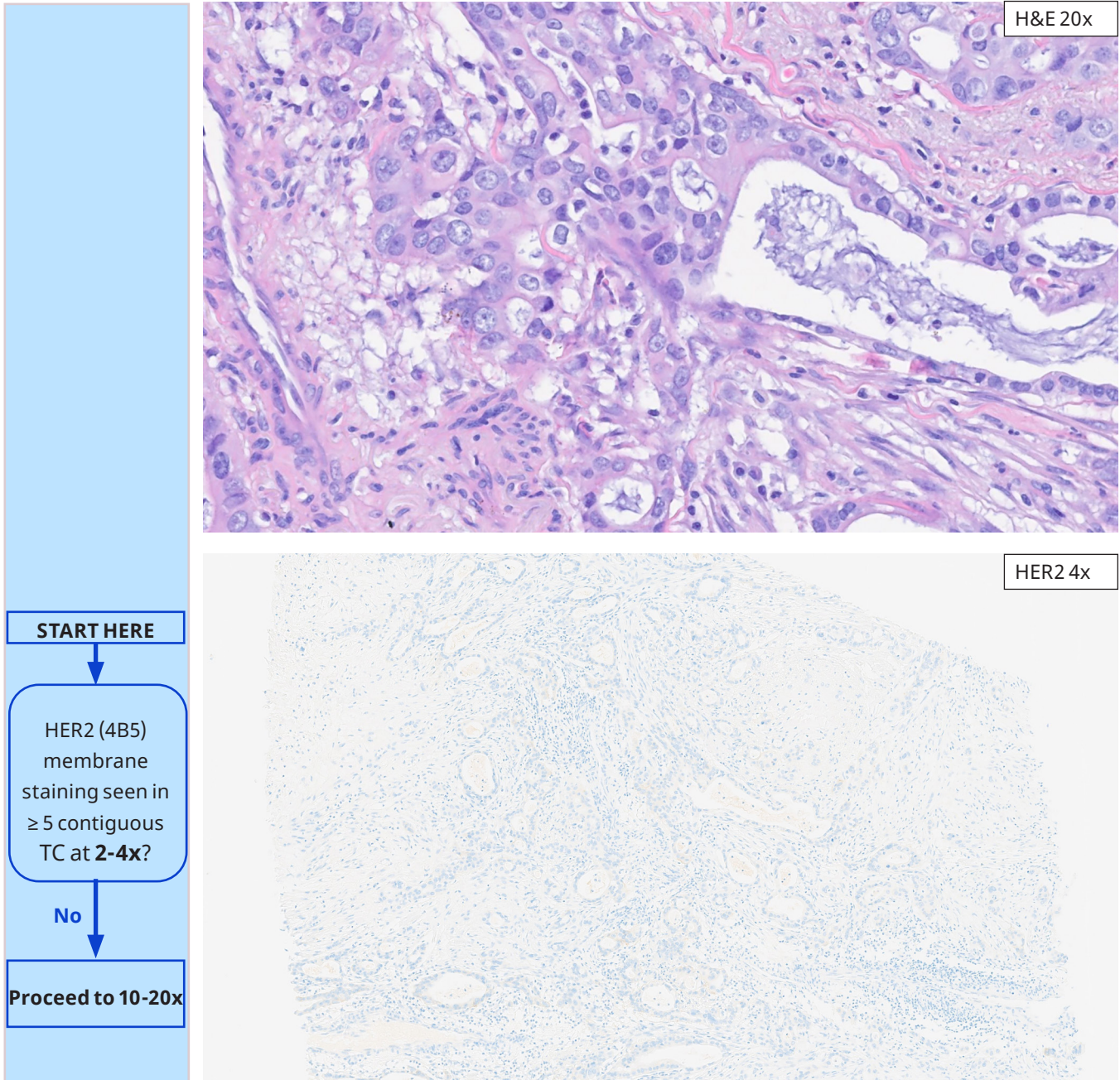


Gallbladder Adenocarcinoma Case: IHC score 3+. At 10x and 20x, homogeneous strong basolateral membrane staining in $\geq 95\%$ of tumor cells.

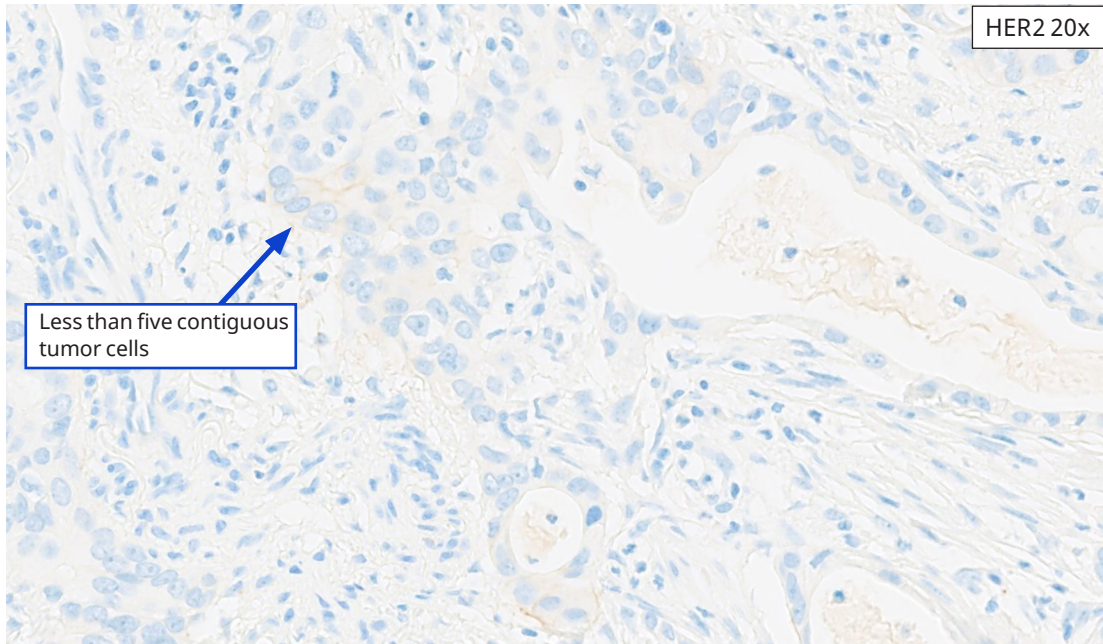
BTC Biopsy Reference Images

HER2 IHC Score 0

These cases exhibit either an absence of appreciable HER2 IHC signal of tumor cells, even at higher magnification (40x objective), or membrane staining in < 5 contiguous tumor cells.



Gallbladder Adenocarcinoma Biopsy Case: IHC score 0. At 4x, no discernable membrane staining is present.



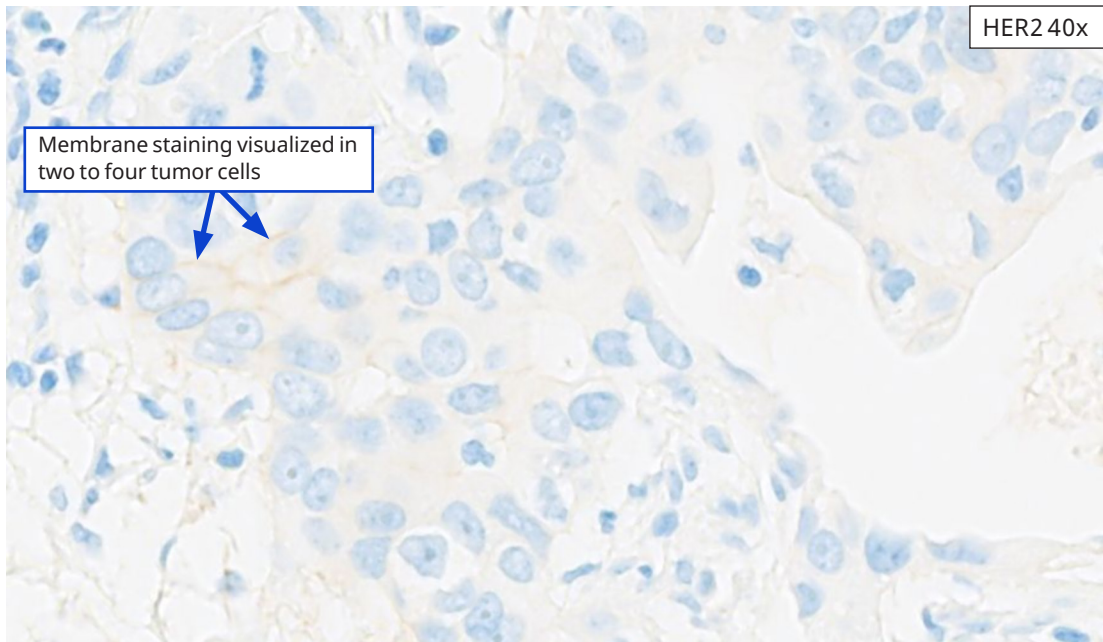
HER2 20x

Less than five contiguous tumor cells

HER2 (4B5) membrane staining seen in ≥ 5 contiguous TC at 10-20x?

No

Proceed to 40x



HER2 40x

Membrane staining visualized in two to four tumor cells

HER2 (4B5) membrane staining seen in ≥ 5 contiguous TC at 40x?

No

Case is HER2 0

Gallbladder Adenocarcinoma Biopsy Case: IHC score 0. Using both 20x and at 40x objectives, fewer than five (5) contiguous tumor cells (arrow- top panel) demonstrate partial membrane staining, excluding IHC scores of 2+ and 1+, respectively, for this case. Membrane staining that can be visualized using 40x objective (arrows- lower panel) is seen in two to four tumor cells, rendering this case a borderline between IHC score 0 and IHC score 1+. This case has an IHC score of 0.

BTC Biopsy Reference Images

HER2 IHC Score 1+

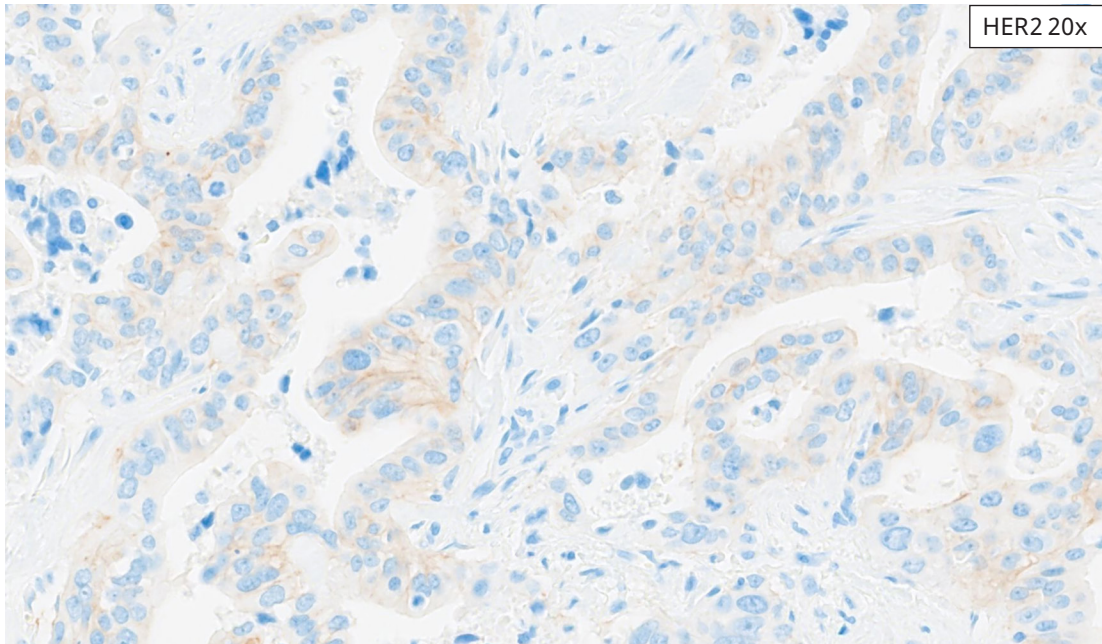
These cases exhibit a faint/barely perceptible HER2 IHC membranous staining of ≥ 5 contiguous tumor cells, requiring higher magnification (40x objective) for clear visualization.

The figure consists of a flowchart on the left and two microscopy images on the right. The flowchart starts with a box labeled "START HERE" with a downward arrow pointing to a rounded rectangle containing the question: "HER2 (4B5) membrane staining seen in ≥ 5 contiguous TC at 2-4x?". Below this question is a downward arrow labeled "No" pointing to a box labeled "Proceed to 10-20x".

The top microscopy image is an H&E stained section at 20x magnification, showing a dense population of tumor cells with prominent nuclei and pink cytoplasm/extracellular matrix. A label "H&E 20x" is in the top right corner.

The bottom microscopy image is an immunohistochemistry (IHC) section at 4x magnification, showing the same tissue area with blue counterstain and faint brown membrane staining on the tumor cells. A label "HER2 4x" is in the top right corner.

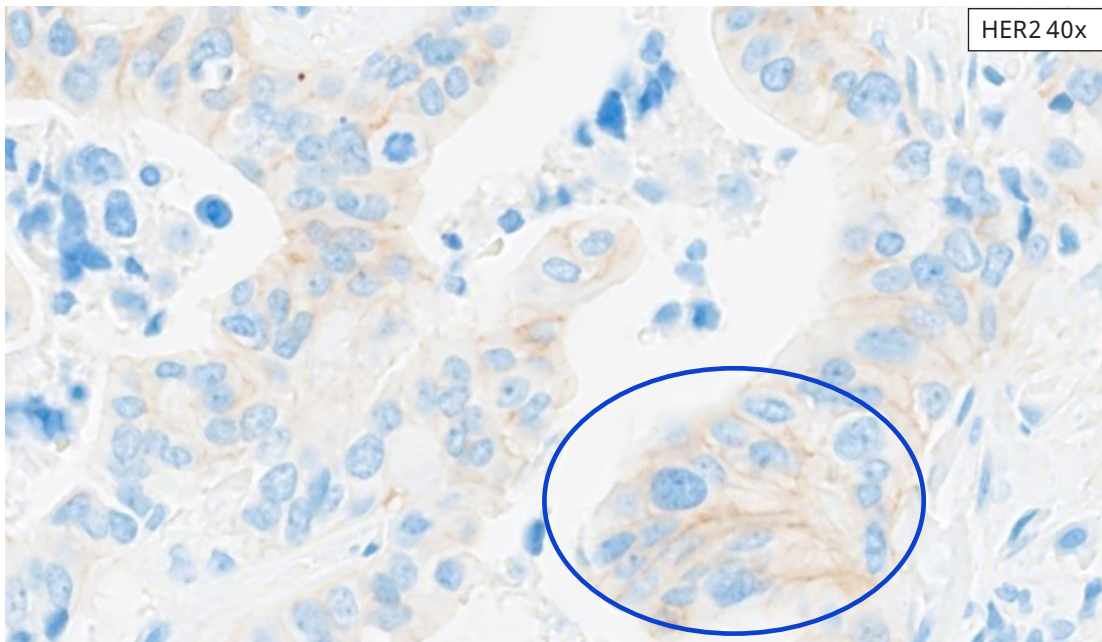
Cholangiocarcinoma Biopsy Case: IHC score 1+. At 4x, no discrete membrane staining is seen, excluding IHC score 3+ for this case.



HER2 (4B5) membrane staining seen in ≥ 5 contiguous TC at 10-20x?

No

Proceed to 40x



HER2 (4B5) membrane staining seen in ≥ 5 contiguous TC at 40x?

Yes

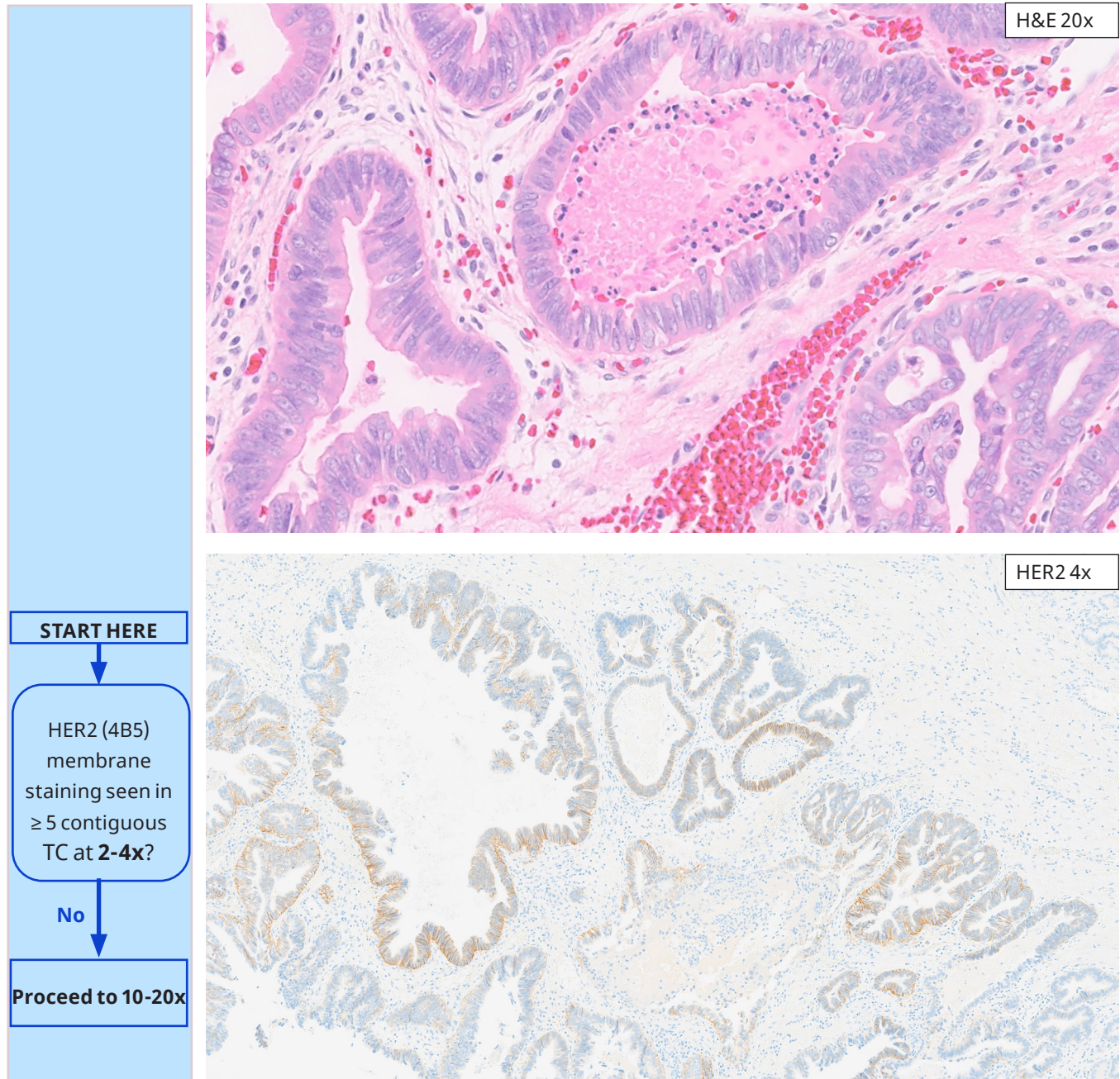
Case is HER2 1+

Cholangiocarcinoma Biopsy Case: IHC score 1+. At 20x, fewer than five (5) contiguous tumor cells demonstrate partial membrane staining, excluding IHC score of 2+. At 40x, membrane staining is seen in at least five contiguous tumor cells (oval).

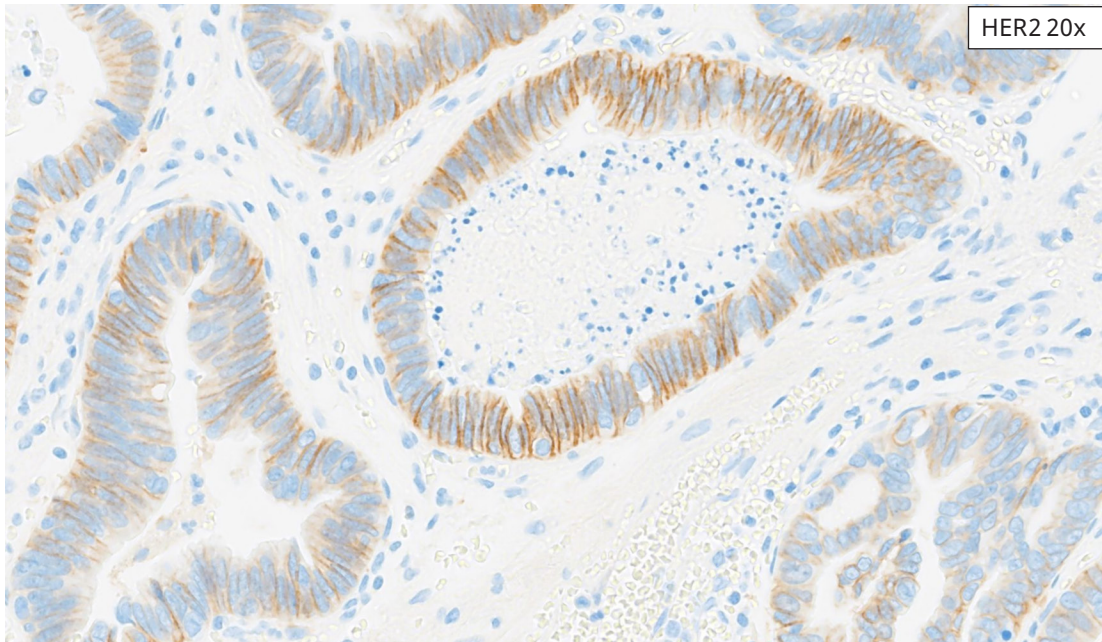
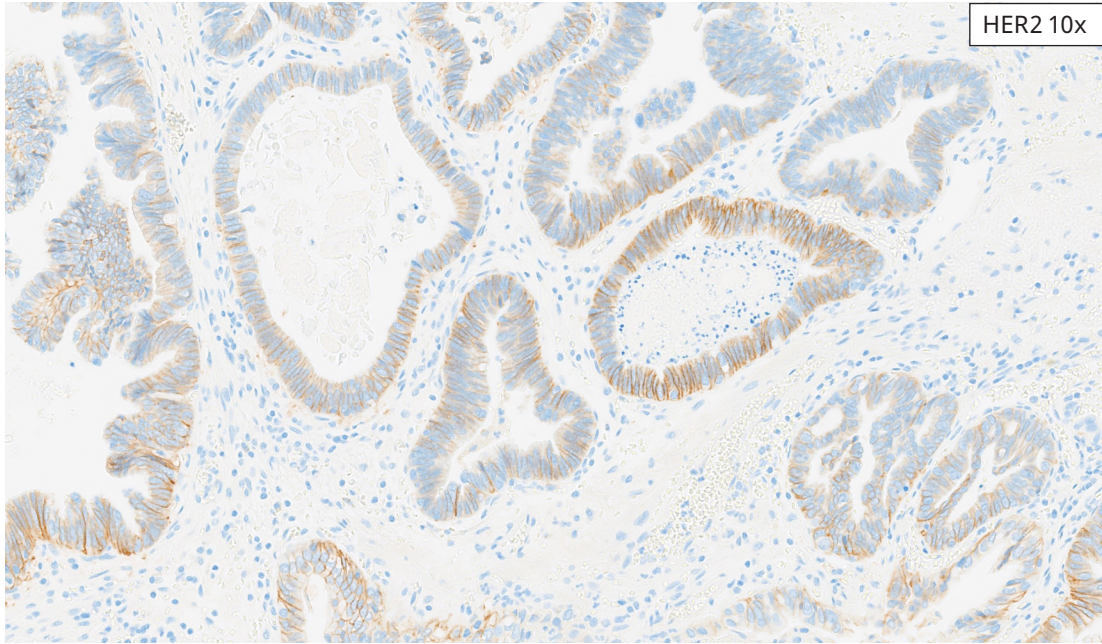
BTC Biopsy Reference Images

HER2 IHC Score 2+

These cases exhibit HER2 IHC signal of weak to moderate membranous staining in ≥ 5 contiguous tumor cells, where tumor cell membrane staining can be visualized with 10x and/or 20x objectives.



Cholangiocarcinoma Biopsy Case: IHC score 1+. At 4x, no discrete membrane staining is seen, excluding IHC score 3+ for this case.



HER2 (4B5) membrane staining seen in ≥ 5 contiguous TC at **10-20x**?

Yes

Case is HER2 2+

Cholangiocarcinoma Biopsy Case: IHC score 2+. At 10-20x, basolateral membrane staining can be seen in ≥ 5 contiguous tumor cells, consistent with IHC 2+.

BTC Biopsy Reference Images

HER2 IHC Score 3+

These cases exhibit HER2 IHC signal of strong membranous staining in ≥ 5 contiguous tumor cells, where tumor cell membrane staining can be visualized with 2x and/or 4x objectives.

The figure consists of a flowchart on the left and two microscopy images on the right. The flowchart starts with a box labeled "START HERE" with a downward arrow pointing to a rounded rectangle containing the text "HER2 (4B5) membrane staining seen in ≥ 5 contiguous TC at 2-4x?". Below this is a box labeled "Yes" with a downward arrow pointing to a final box labeled "Case is HER2 3+". To the right of the flowchart are two images. The top image is an H&E stained section at 20x magnification, showing glandular structures of a tumor. The bottom image is an IHC stained section at 4x magnification, showing strong brown membranous staining on the tumor cells.

H&E 20x

HER2 4x

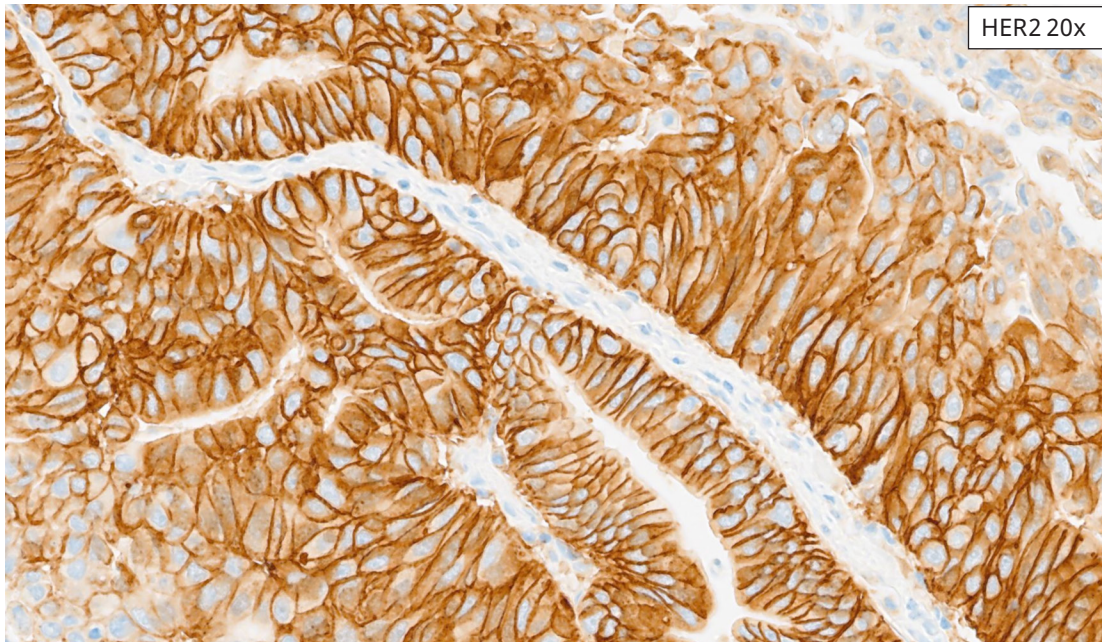
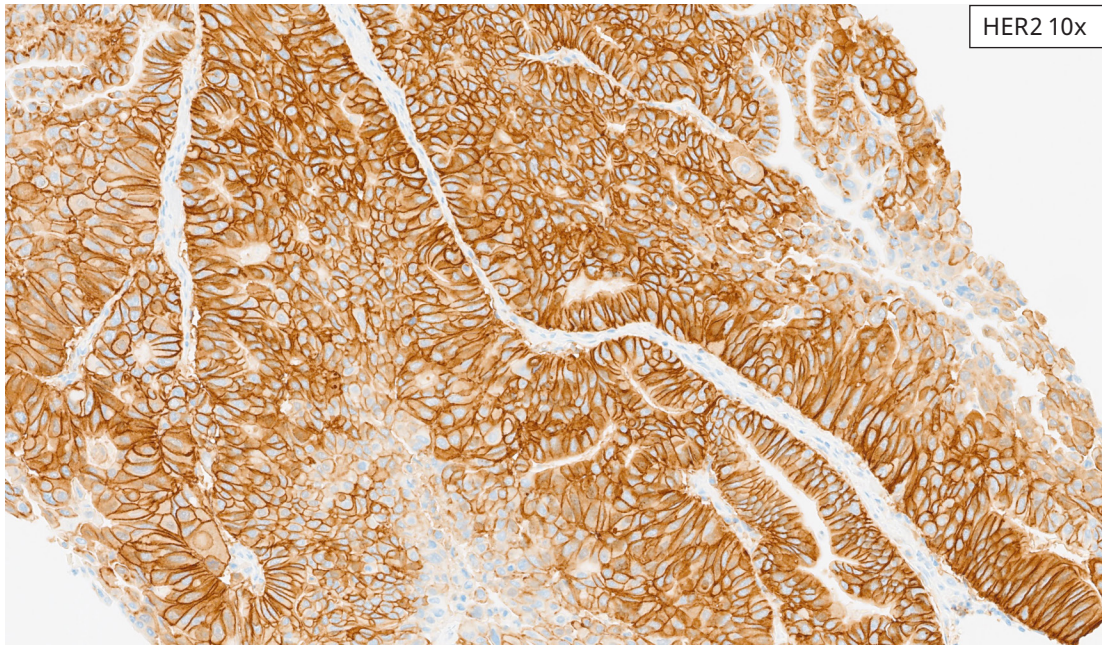
START HERE

HER2 (4B5) membrane staining seen in ≥ 5 contiguous TC at 2-4x?

Yes

Case is HER2 3+

Gallbladder Adenocarcinoma Biopsy Case: IHC score 3+. At 4x, membrane staining is easily visualized in ≥ 5 contiguous tumor cells, consistent with IHC score 3+.



Gallbladder Adenocarcinoma Biopsy Case: IHC score 3+. At 20x, homogeneous strong basolateral and circumferential membrane staining is seen. Accompanying weak to moderate cytoplasmic staining is also present, but does not obscure membrane staining.

BTC Borderline Reference Images

The most difficult area of interpretation is cases that fall on the borderline between an intensity level of “1+” and “2+”, or where there is a mixture of different expression levels. Here are some tips for handling these cases:

1. Evaluate the borderline case within the context of unambiguous “1+” and “2+” cases to regain perspective.
2. Use the 20x and 40x objectives to help differentiate between 1+ and 2+ staining intensities. If the question is between a 3+ or 2+ then rely on the differences seen with the 4x and 10x objectives.
3. Remember that pattern plays a primary role in the score. Both complete and incomplete membranous staining can be considered in BTC, refer to [Table 1](#).
4. Scan complete tissue section to ensure scoring in well-preserved and well stained areas only.
5. Consider repeating the staining on another section or repeat staining on sections from a different block if none of the above suggestions resolve the diagnosis.

Examples of borderline cases are shown on the following pages.

- **HER2 1+, Borderline with 2+**
- **HER2 2+, Borderline with 1+**
- **HER2 2+, Borderline with 3+**
- **HER2 3+, Borderline with 2+**
- **HER2 3+, Borderline with 0**

BTC Borderline Reference Images

HER2 1+, Borderline with 2+

These cases demonstrate some HER2 membrane staining that can be seen at 10x to 20x, close to, but < 10% of tumor cells (resections) or in less than 5 contiguous tumor cells (biopsies).

START HERE

HER2 (4B5) membrane staining seen in $\geq 10\%$ TC at **2-4x**?

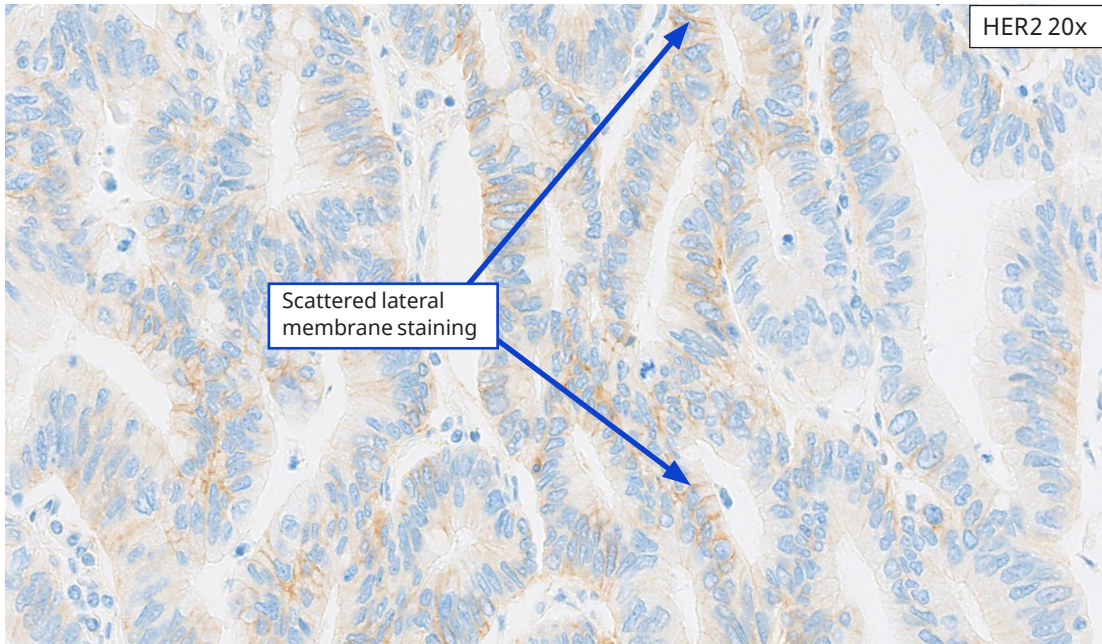
No

Proceed to 10-20x

H&E 20x

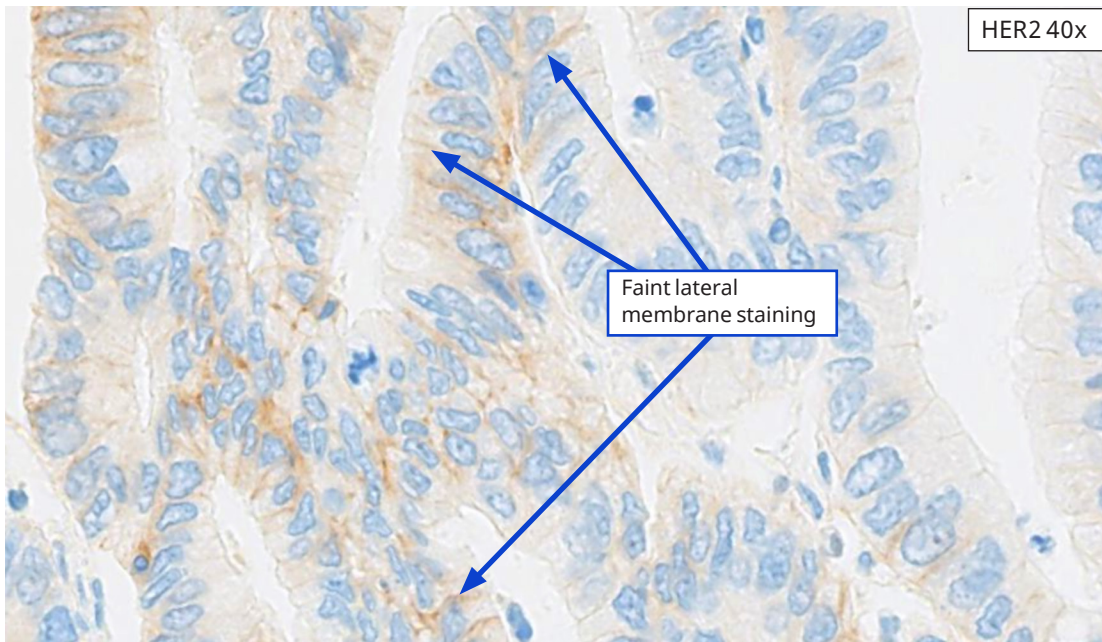

HER2 4x

Borderline 1+ (near 2+) Cholangiocarcinoma resection Case: IHC score 1+ (borderline with 2+). Although vague, ill-defined staining can be observed at 4x, no discrete membrane staining is seen, thus excluding IHC score 3+ for this case.



HER2 20x

Scattered lateral membrane staining



HER2 40x

Faint lateral membrane staining

Borderline 1+ (near 2+) Cholangiocarcinoma resection Case: IHC score 1+ (borderline with 2+). Scattered lateral membranes can be seen with 20x objective, accounting for ~ 5% (but < 10%) of tumor cells in this field (arrows), thus excluding IHC score 2+ for this case. At 40x, faint lateral membranes are seen in $\geq 10\%$ of tumor cells (arrows), consistent with IHC score of 1+.

BTC Borderline Reference Images

HER2 2+, Borderline with 1+

These cases demonstrate HER2 membrane staining that can be seen at 10x to 20x, in 10% or just over 10% of tumor cells (resections) or in 5 or just over 5 contiguous tumor cells (biopsies).

START HERE

HER2 (4B5) membrane staining seen in $\geq 10\%$ TC at **2-4x**?

No


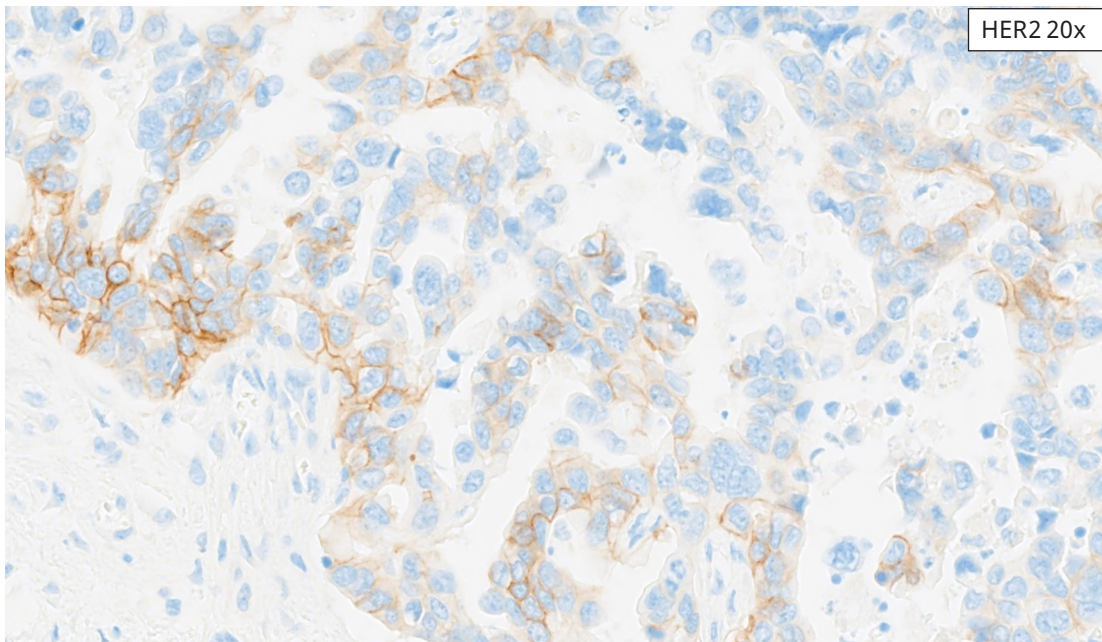
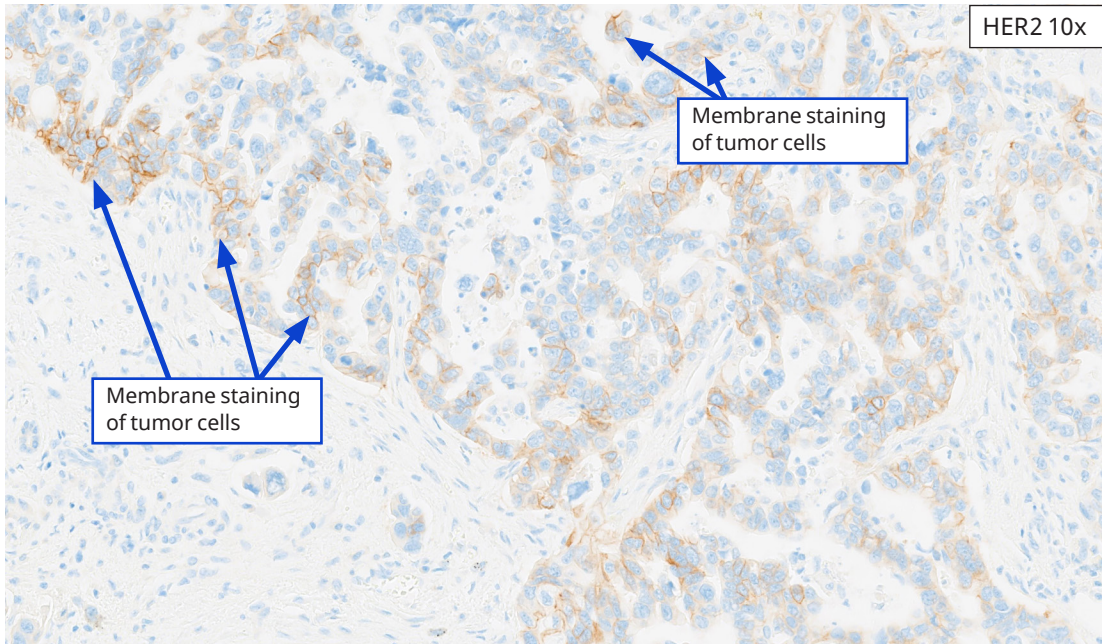
Proceed to 10-20x

H&E 20x

HER2 4x

Membrane staining of tumor cells

Borderline 2+ Cholangiocarcinoma Resection Case: IHC score 2+ (borderline with 1+). At 4x, membrane staining is seen in $< 1\%$ of tumor cells (arrow), so IHC score 3+ is excluded for this case.



Borderline 2+ Cholangiocarcinoma Resection Case: IHC score 2+ (borderline with 1+). At 10-20x, 15% of tumor cells (arrows) demonstrate membrane staining, consistent with IHC score of 2+ (borderline with 1+).

BTC Borderline Reference Images

HER2 2+, Borderline with 3+

These cases exhibit some membrane staining at 4x, but in < 10% of tumor cells (resections) or in < 5 contiguous tumor cells (biopsies).

START HERE

HER2 (4B5) membrane staining seen in $\geq 10\%$ TC at **2-4x**?

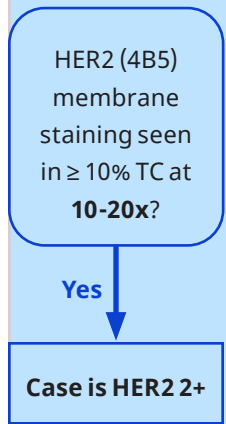
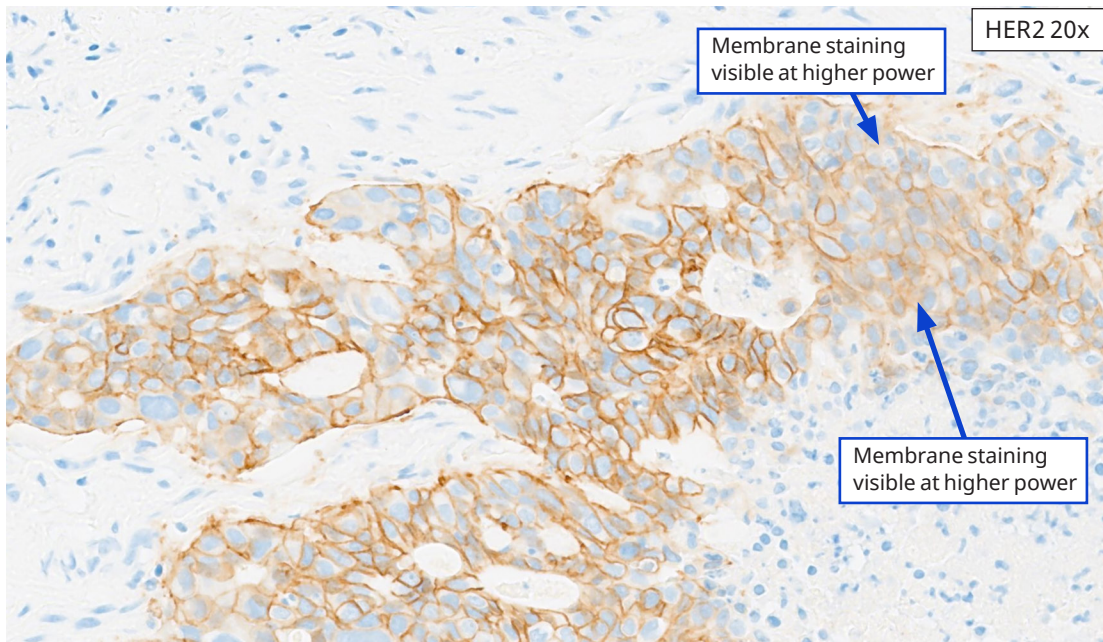
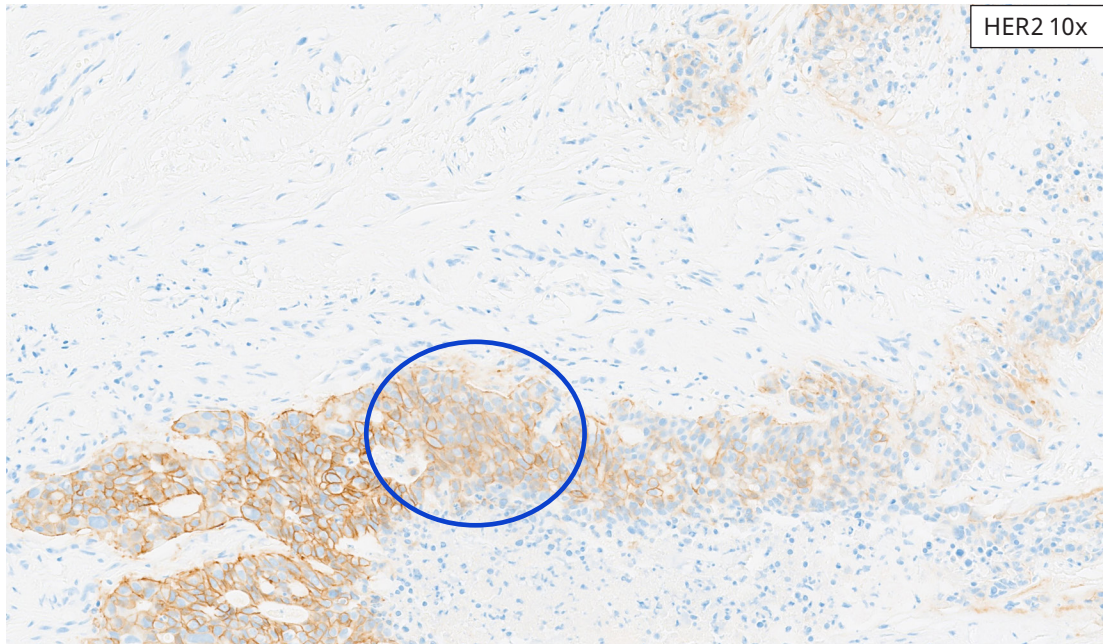
No

Proceed to 10-20x

H&E 20x

HER2 4x

Borderline 2+ (near 3+) Gallbladder Adenocarcinoma Resection Case: IHC score 2+ (borderline with 3+). At 4x, possible hints of membrane staining are noted, but in < 10% of tumor cells, (lower left of image), thus excluding IHC score of 3+ for this case.



Borderline 2+ (near 3+) Gallbladder Adenocarcinoma Resection Case: IHC score 2+ (borderline with 3+). At 10x and at 20x, membrane staining can be visualized in $\geq 10\%$ of tumor cells, consistent with IHC score of 2+. Note: some membrane staining that was not as clearly resolved/visualized at 10x are definitely visible at 20x (oval and arrows). This is a good example of the variation of intensities that fall within the 2+ IHC score.

BTC Borderline Reference Images

HER2 3+, Borderline with 2+

These cases exhibit membrane staining at 4x in 10% or just over 10% (resections) or 5 or just over 5 contiguous tumor cells (biopsies).

The figure consists of a flowchart on the left and two histology images on the right. The flowchart starts with a box labeled "START HERE" with a downward arrow pointing to a rounded rectangle containing the text "HER2 (4B5) membrane staining seen in $\geq 10\%$ TC at 2-4x?". Below this is a box labeled "Yes" with a downward arrow pointing to a final box labeled "Case is HER2 3+". To the right of the flowchart are two histology images. The top image is an H&E stain at 10x magnification, showing glandular structures of a tumor. The bottom image is an IHC stain for HER2 at 4x magnification, showing brown membrane staining on the tumor cells.

START HERE

HER2 (4B5) membrane staining seen in $\geq 10\%$ TC at 2-4x?

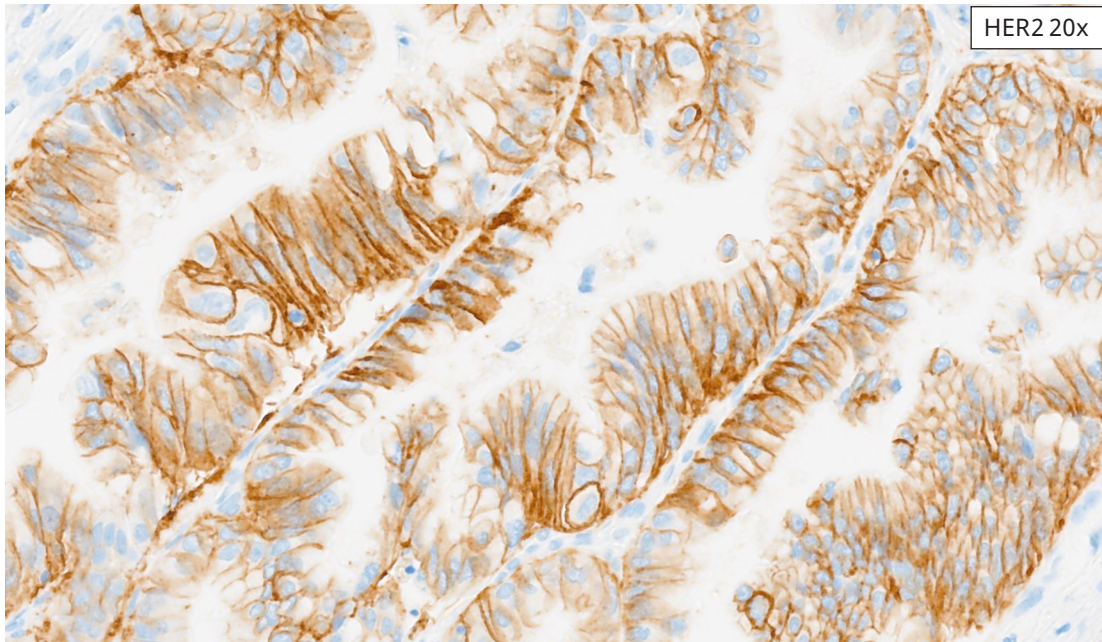
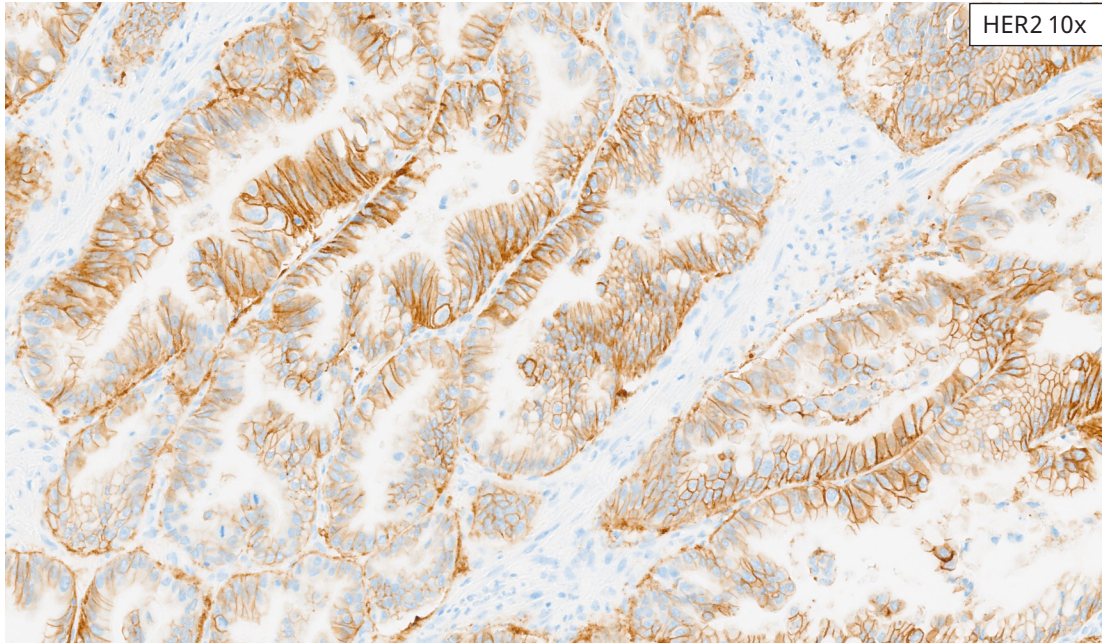
Yes

Case is HER2 3+

H&E 10x

HER2 4x

Borderline 3+ (near 2+) Cholangiocarcinoma Resection Case: IHC score 3+ (borderline with 2+). At 4x, membrane staining is seen in 15% of tumor cells, consistent with IHC score 3+.



Borderline 3+ (near 2+) Cholangiocarcinoma Resection Case: IHC score 3+ (borderline with 2+). At 10x and 20x images demonstrate clearly resolved basolateral membrane staining consistent with 2+ staining.

BTC Borderline Reference Images

HER2 3+, Borderline with 0

These cases exhibit membrane staining at 4x in 10% or just over 10% (resections) or 5 or just over 5 contiguous tumor cells (biopsies).

START HERE

HER2 (4B5) membrane staining seen in $\geq 10\%$ TC at **2-4x**?

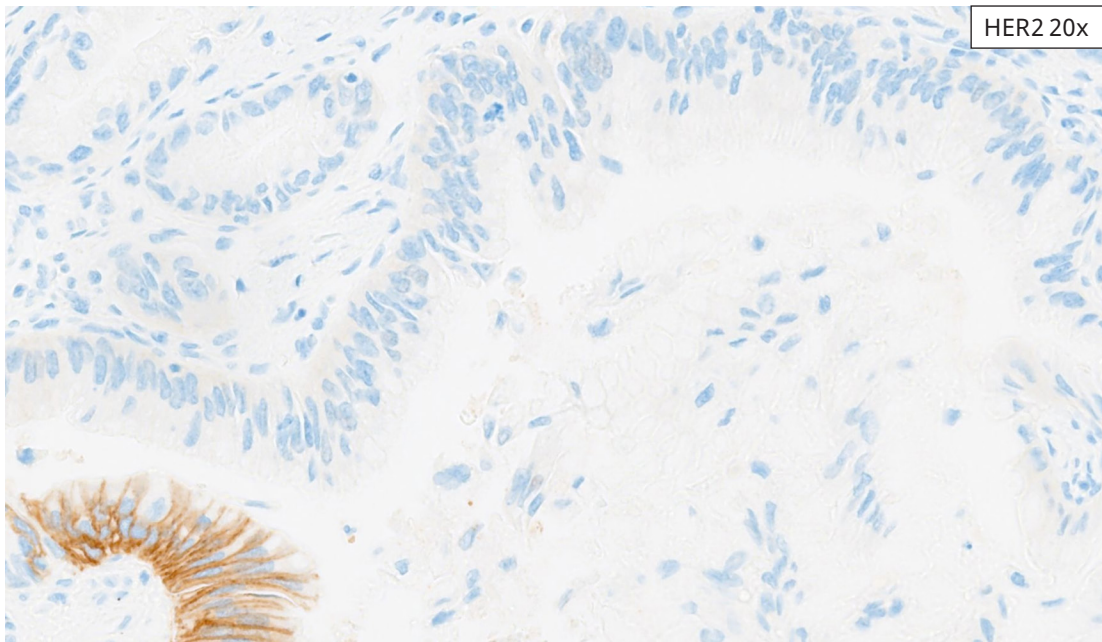
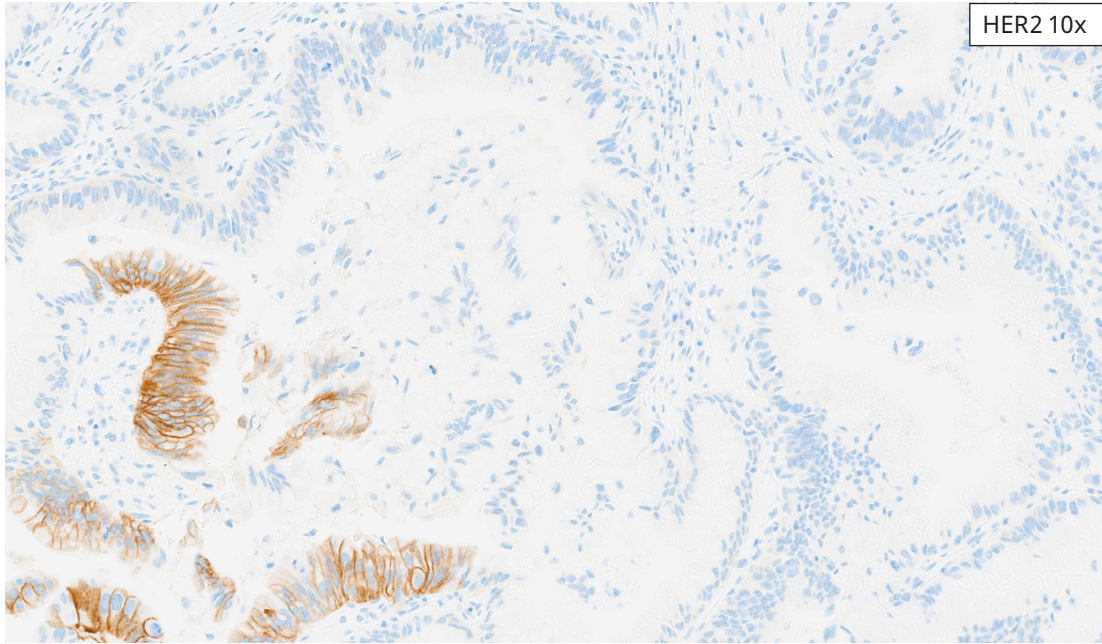
Yes

Case is HER2 3+

H&E 10x

HER2 4x

Borderline 3+ (near 0) Cholangiocarcinoma Resection Case: IHC score 3+ borderline with zero. At 4x, membrane staining is present in 10% of tumor cells, consistent with IHC score 3+. Note that this case is also an example of heterogeneous HER2 over-expression, with the majority of the tumor showing no membrane staining.



Borderline 3+ (near 0) Cholangiocarcinoma Resection Case: IHC score 3+ borderline with zero. Images at 10x and 20x demonstrate heterogeneity of HER2 overexpression that is localized to tumor cells in the left aspect of the image.

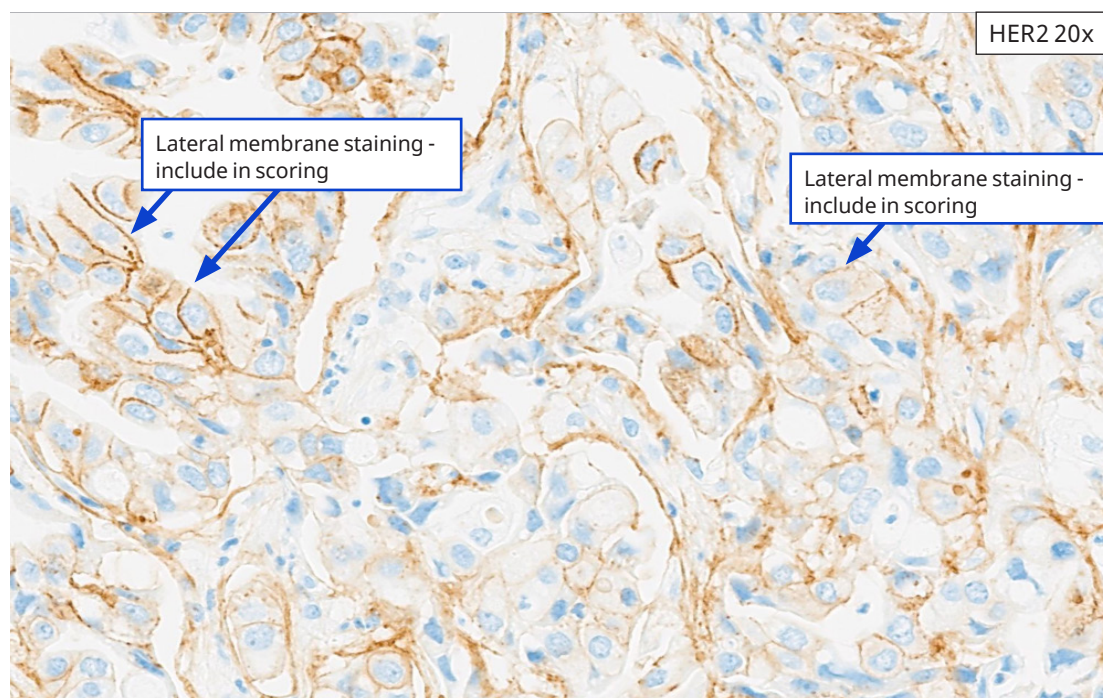
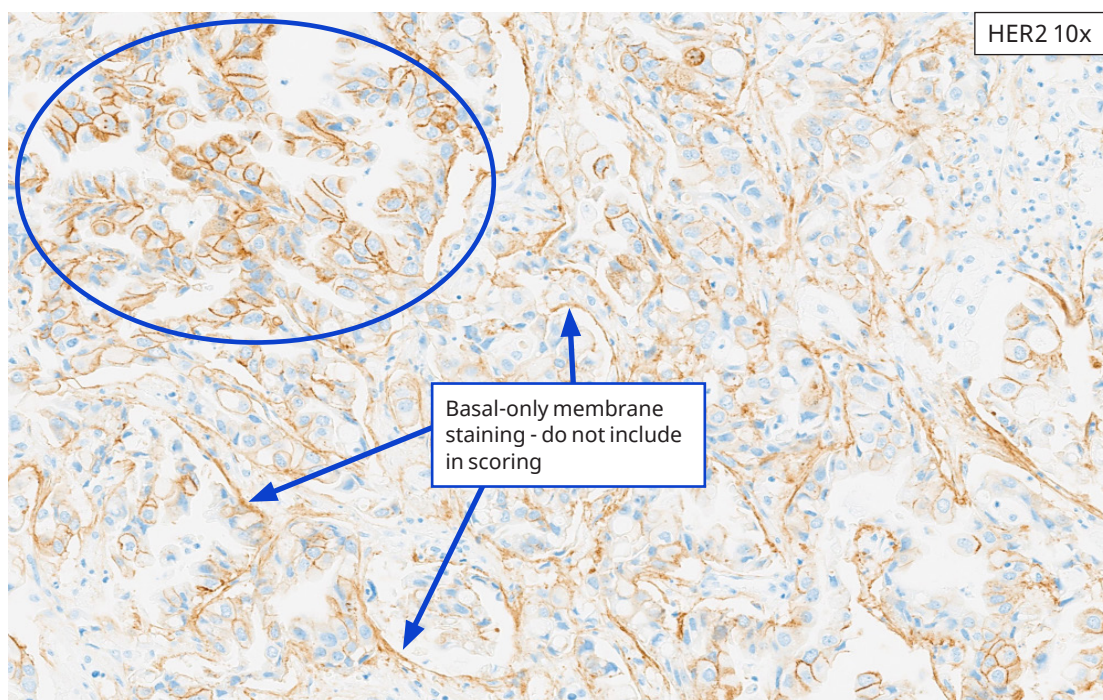Challenging Cases

Atypical Staining Patterns

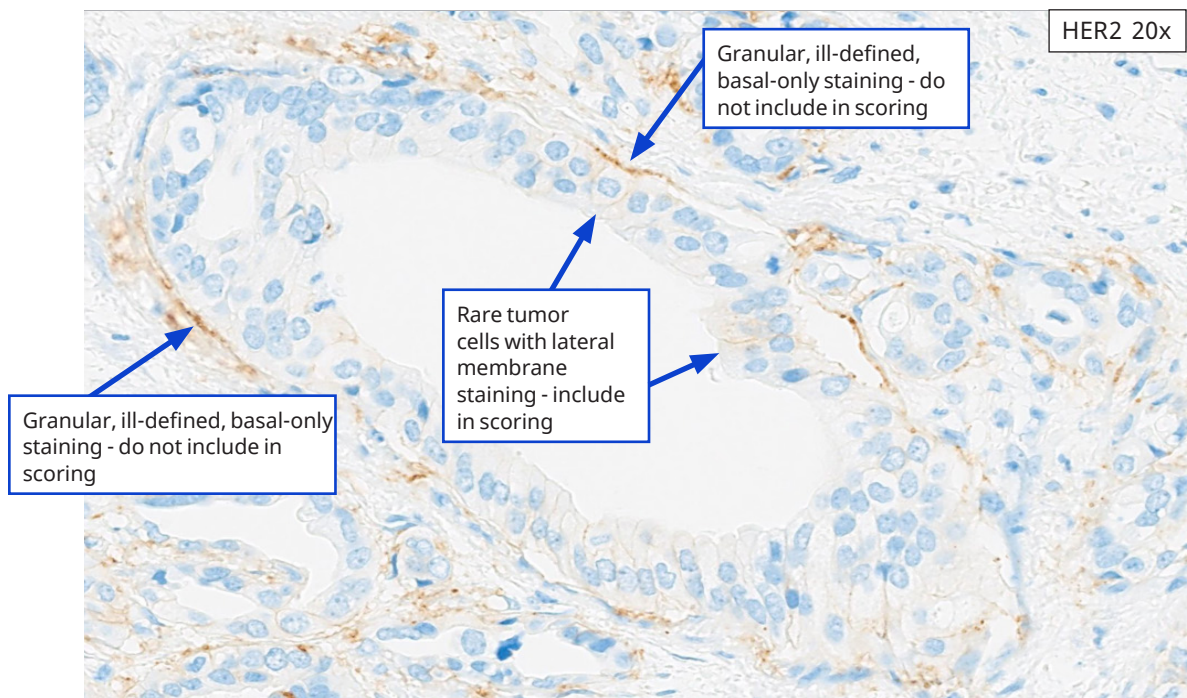
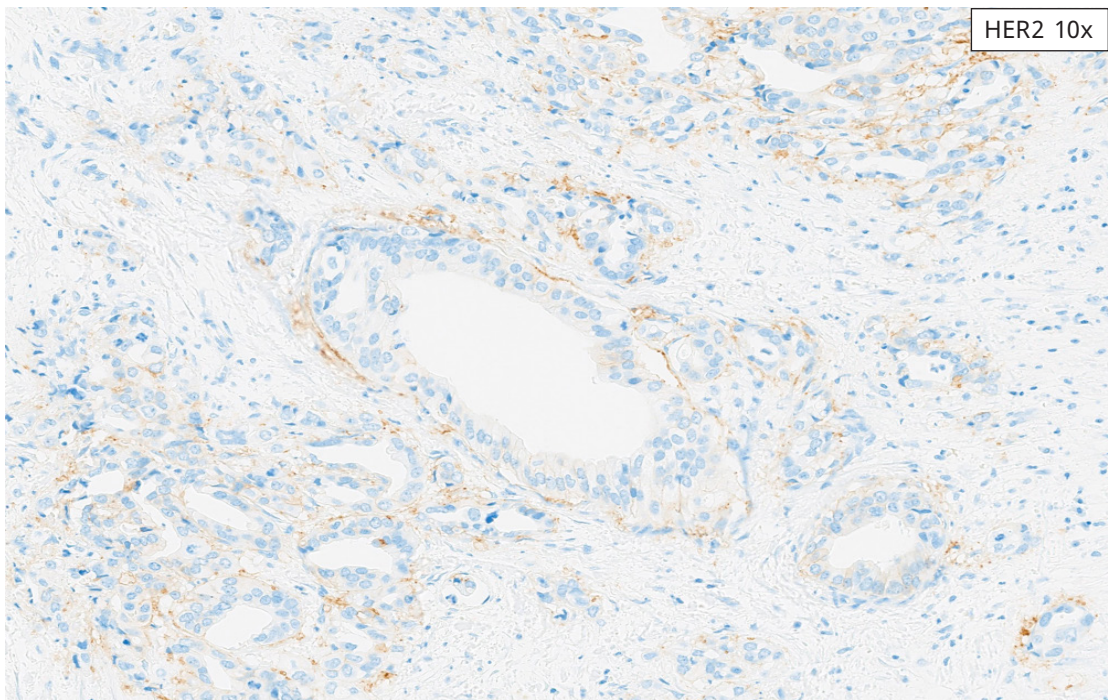
While the vast majority of cases stained with HER2 (4B5) assay have clear staining results, a few cases have been observed that present a challenge in interpretation.

- **Basal-only staining**
- **Apical-only staining**

Challenging Cases: Basal-only Staining

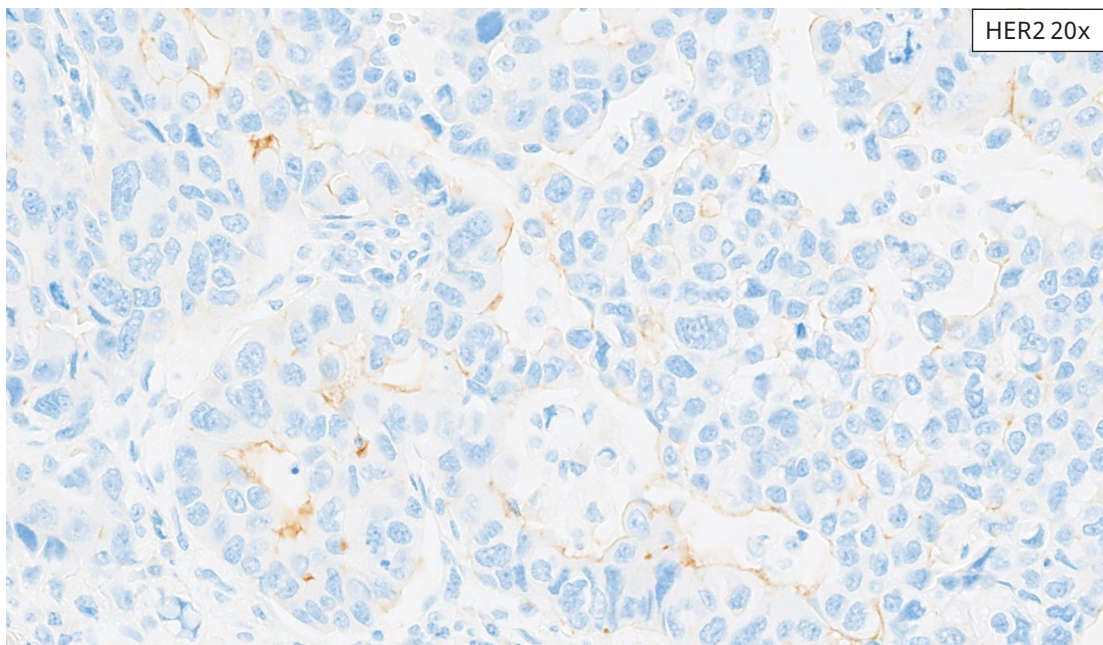
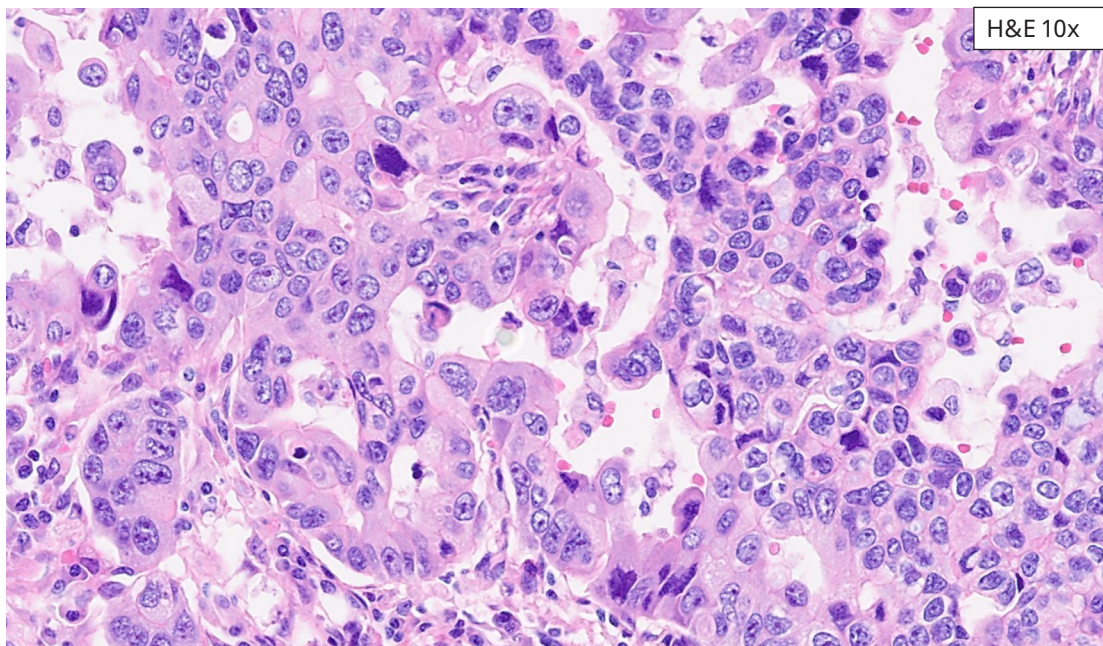


Challenging Gallbladder Adenocarcinoma Case: Images at 10x and at 20x demonstrate a region of moderate to strong basolateral membrane staining (oval). Prominent basal-only staining is seen in the remainder of the field and should not be included when determining IHC score (arrows - top panel). There are scattered tumor cells (arrows - bottom panel) where lateral membrane staining is present, that should be included in determining the IHC score.



Challenging Gallbladder Adenocarcinoma Case: These images demonstrate granular and ill-defined basal-only staining that should not be included as part of the HER2 IHC score (top and left arrows). There are rare tumor cells with lateral membrane staining (center arrows), which should be included as part of the HER2 IHC score.

Challenging Cases: Apical-only Staining



Apical-only Esophageal Adenocarcinoma Case: In this image, the tumor cells demonstrate DAB along the apical surface of the tumor cells. In the absence of basolateral or lateral membrane staining, apical-only staining should not be included in the HER2 IHC score. Note that the cases used to demonstrate specific artifacts may include tumor indications other than BTC, based on tissue availability.

Staining Artifacts

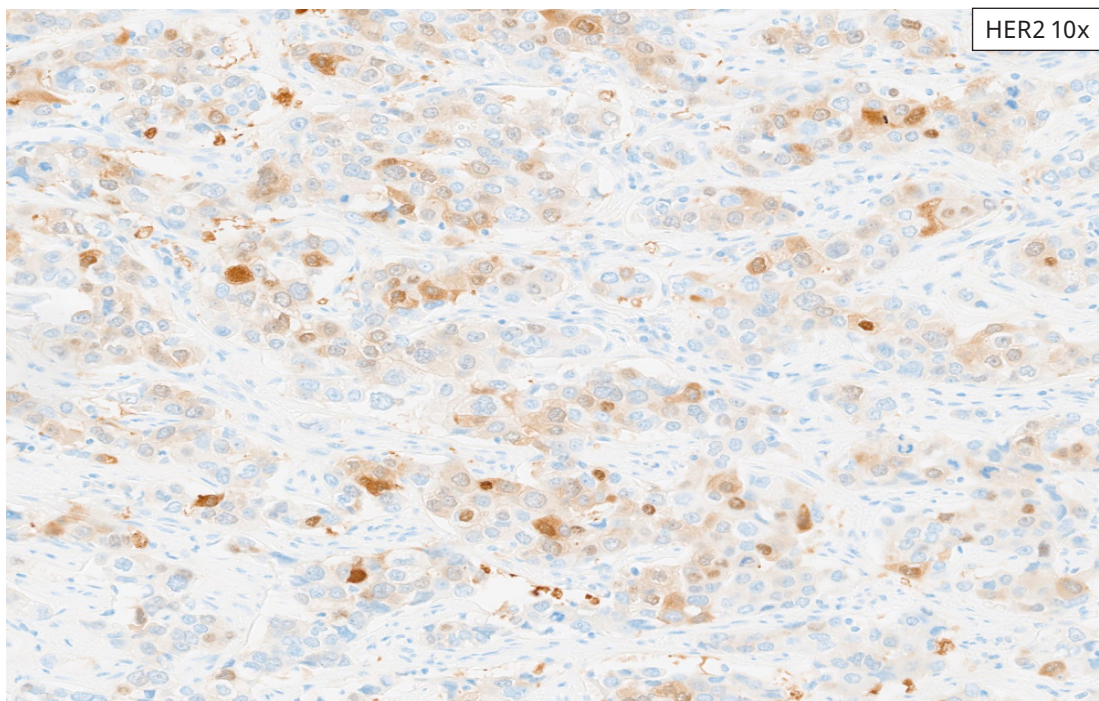
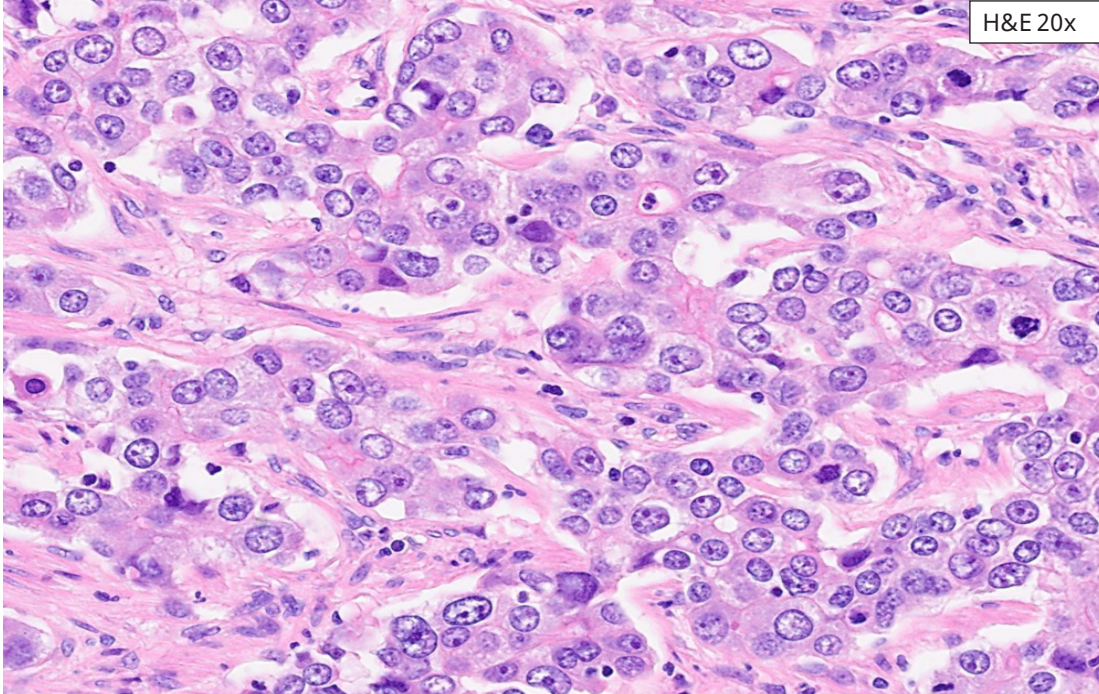
Artifacts noted in this section may be observed on HER2 (4B5) Assay-stained slides. The presence of these artifacts may require repeat staining if they interfere with interpretation of HER2 (4B5) Assay staining. Always review the corresponding Negative Control-stained slide to ensure that non-specific background staining is within acceptable limits.

Examples of staining artifacts are shown on the following pages.

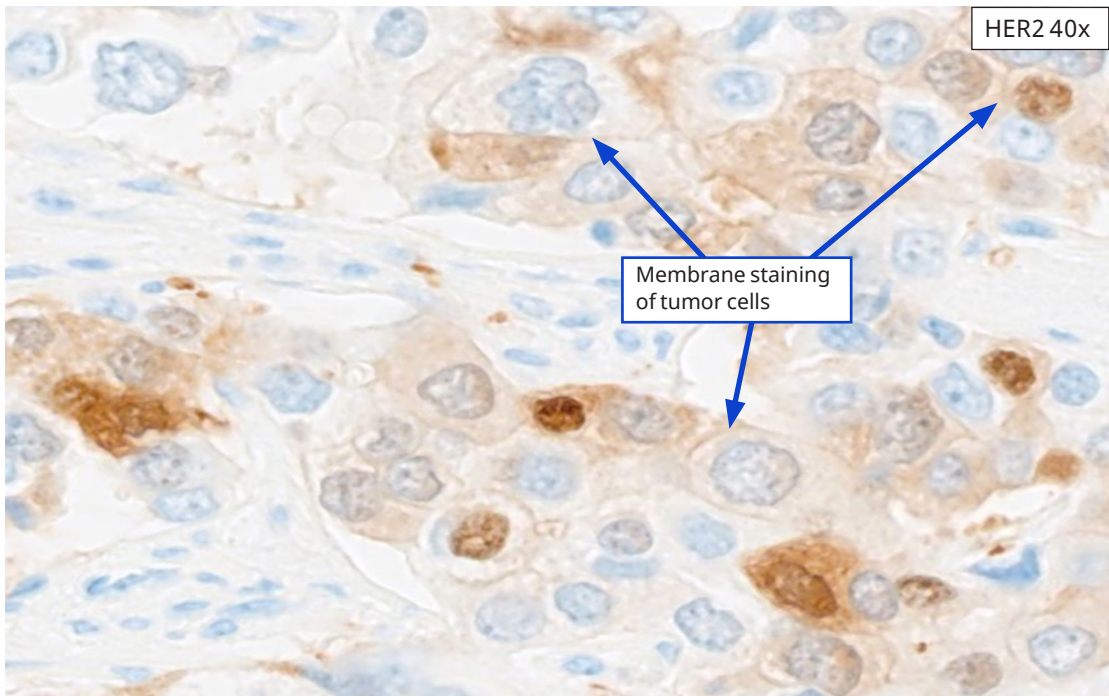
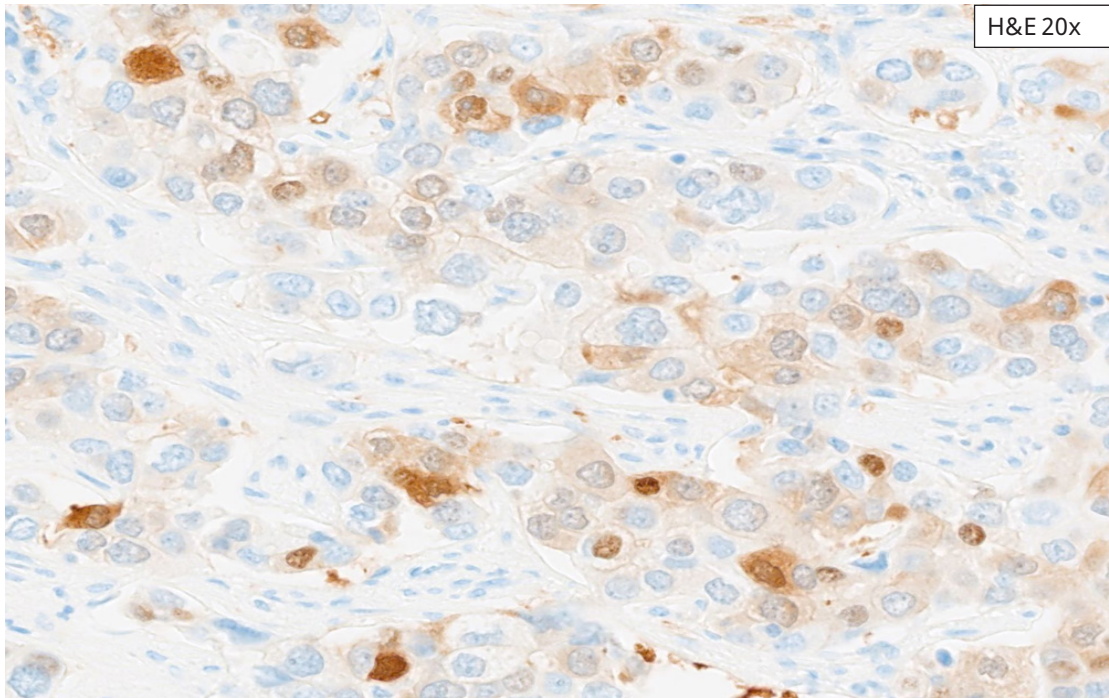
- Cytonuclear staining in Carcinoma Cells, Gallbladder Adenocarcinoma Resection Case 1
- Cytonuclear staining in Carcinoma Cells, Gallbladder Adenocarcinoma Resection Case 2
- Cytonuclear staining in Non-Neoplastic Cells (Hepatocytes), Cholangiocarcinoma Resection Case
- Cytonuclear staining in Non-Neoplastic Cells (Epithelium), Cholangiocarcinoma Resection Case

Staining Artifacts: Cytonuclear Staining in Carcinoma Cells

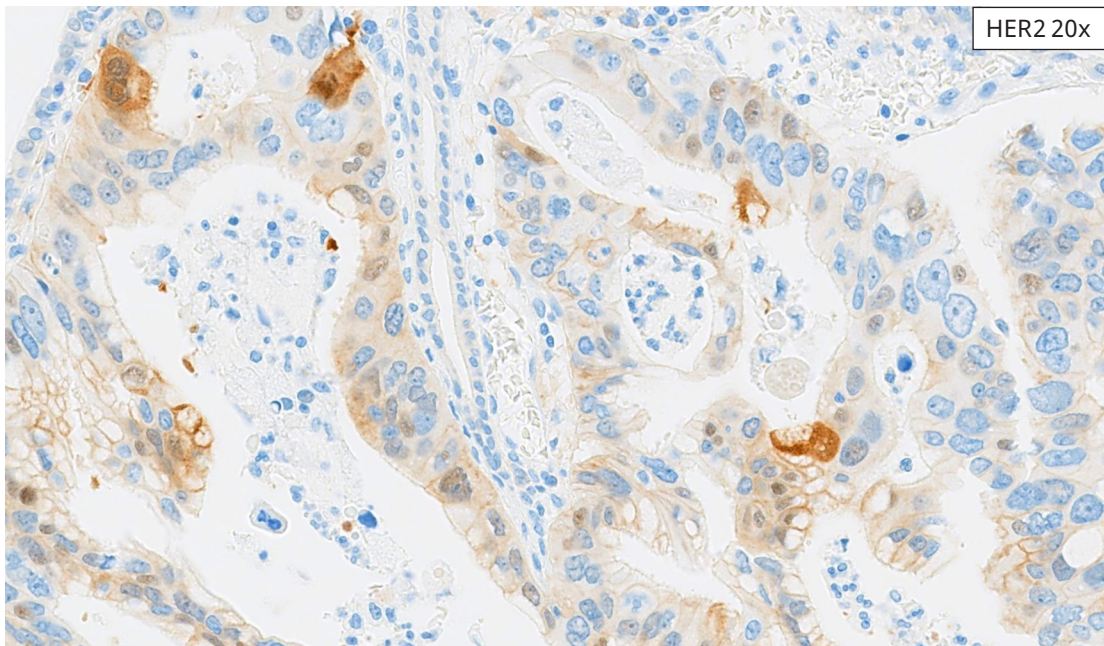
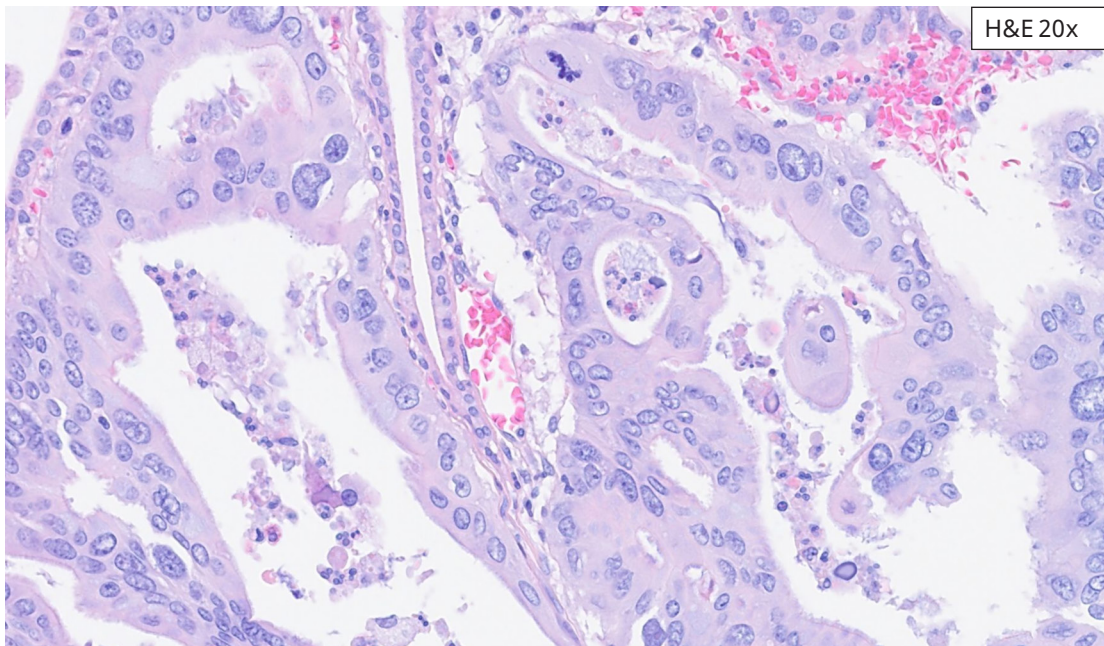
These cases exhibit staining in the cytoplasmic and/or nuclear compartments. Cytonuclear staining may be present with or without membrane staining. **HER2 IHC score should include ONLY membrane staining; cytonuclear staining should not contribute to the IHC score.**



Cytonuclear Gallbladder Adenocarcinoma Resection Case 1: IHC Score 0. The 10x image demonstrates tumor cells with faint to strong cytoplasmic and cytonuclear staining. Less than 10% of tumor cells demonstrate faint/weak membrane staining, consistent with IHC score 0. Only tumor cells demonstrating membrane staining should be evaluated to determine the HER2 IHC score. Those cells with only cytonuclear staining should be excluded.



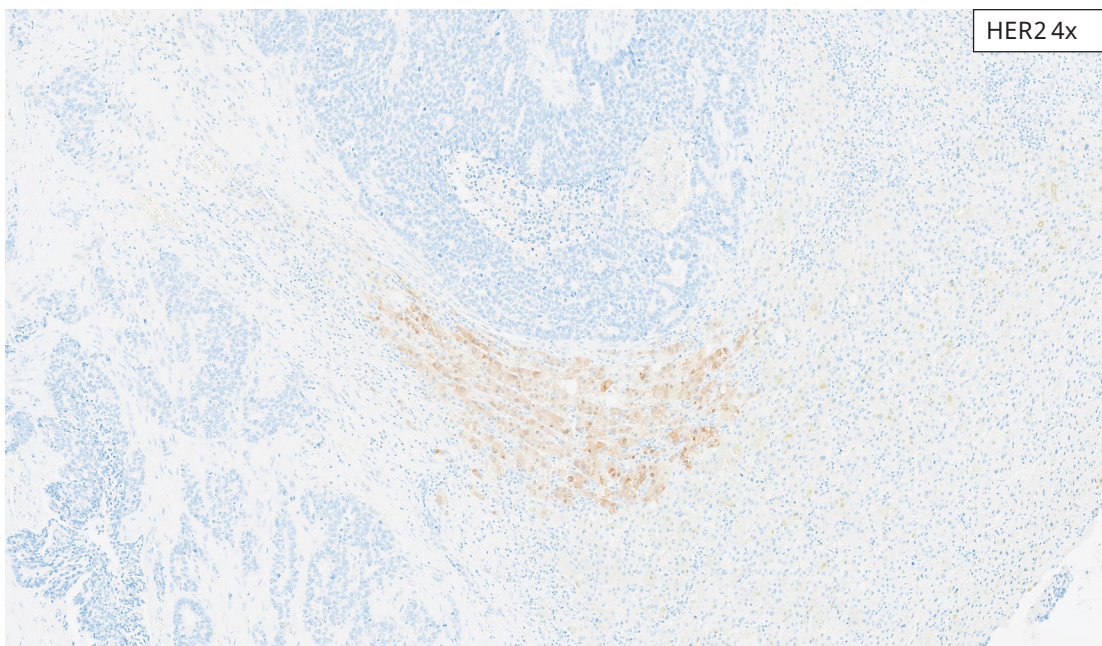
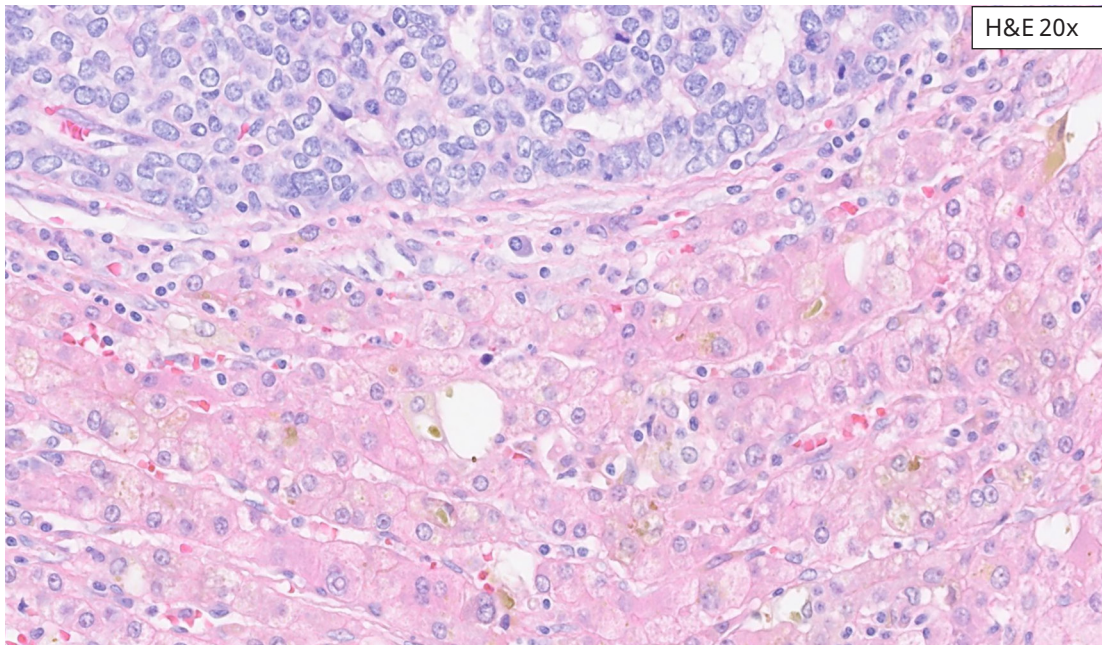
Cytonuclear Gallbladder Adenocarcinoma Resection Case 1: IHC Score 0. Higher magnification images demonstrate the range of intensity of cytonuclear staining. 20x and 40x images demonstrate examples of tumor cells with membrane staining (arrows) which should be included in determining HER2 IHC score.



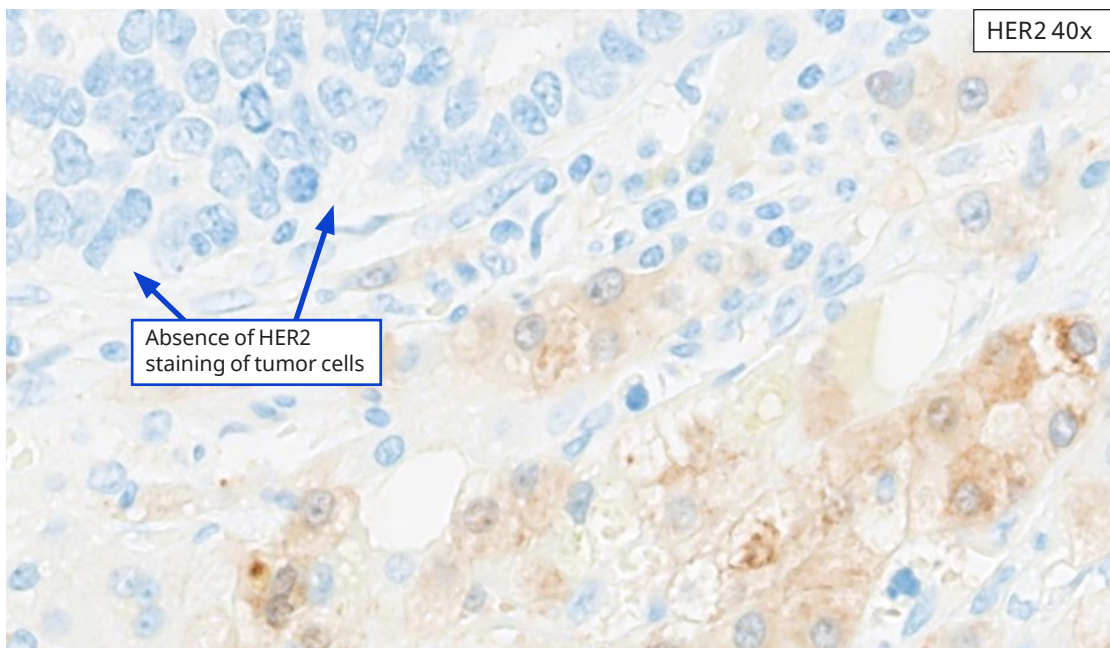
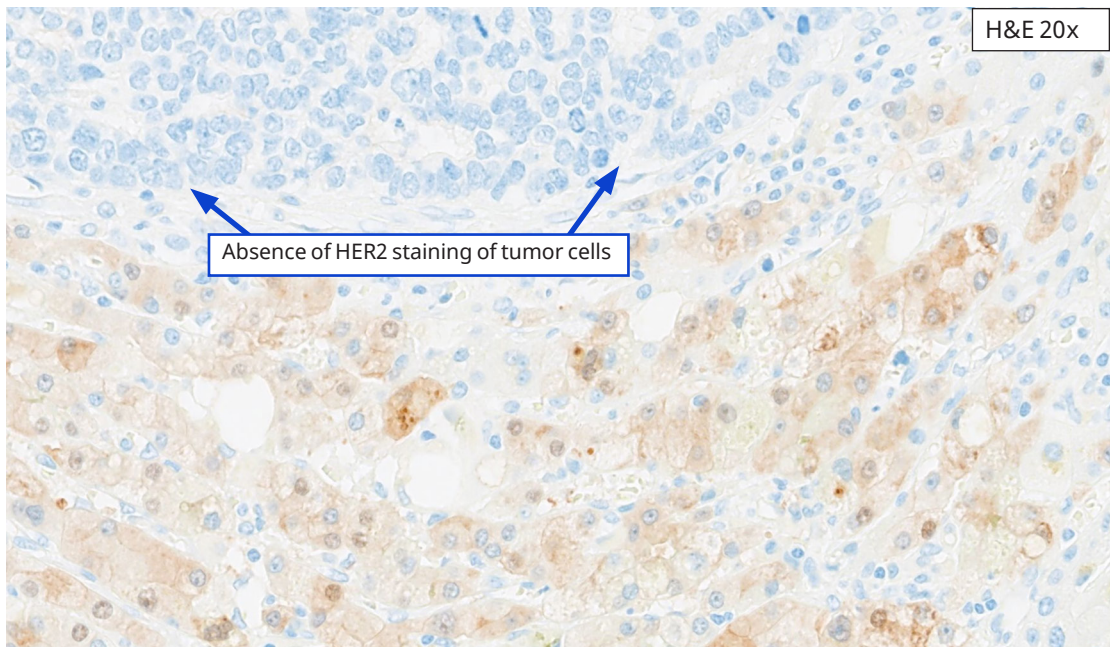
Cytonuclear Gallbladder Adenocarcinoma Resection Case 2: IHC Score 0. The 20x image demonstrates tumor cells with faint to strong cytoplasmic and cytonuclear staining. Less than 10% of tumor cells demonstrate weak to moderate membrane staining, consistent with IHC score 0. Only tumor cells demonstrating membrane staining should be evaluated to determine the HER2 IHC score. Those cells with only cytonuclear staining should be excluded.

Staining Artifacts: Cytonuclear Staining in Non-Neoplastic Cells

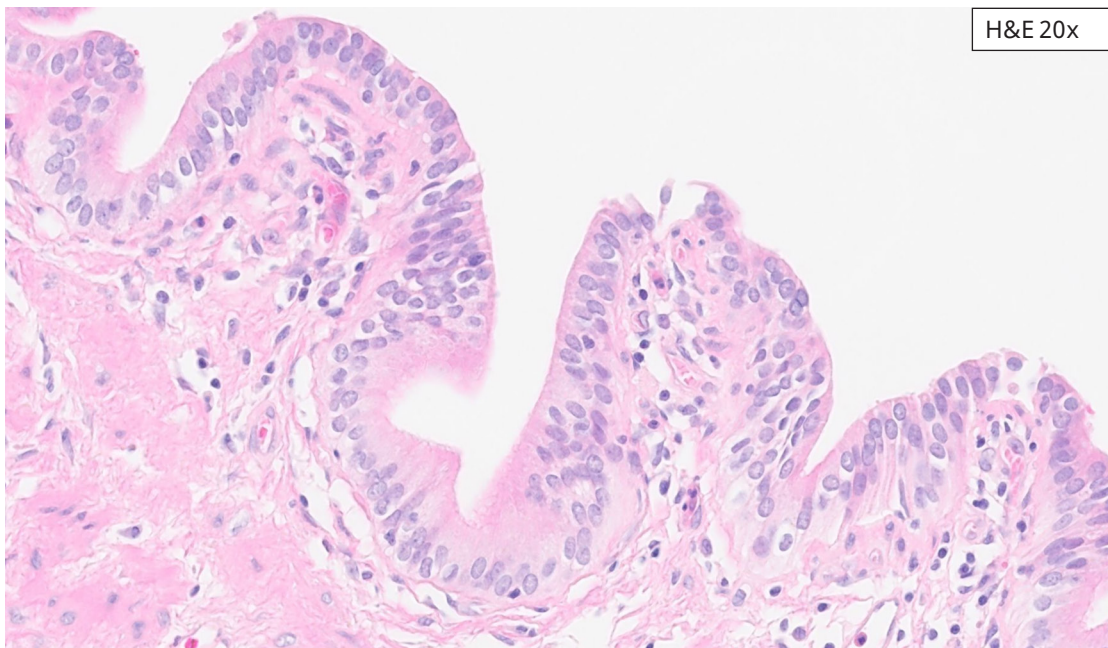
These cases exhibit HER2 IHC signal in the cytoplasmic and/or nuclear compartments of non-neoplastic cells that are adjacent to tumor cells.



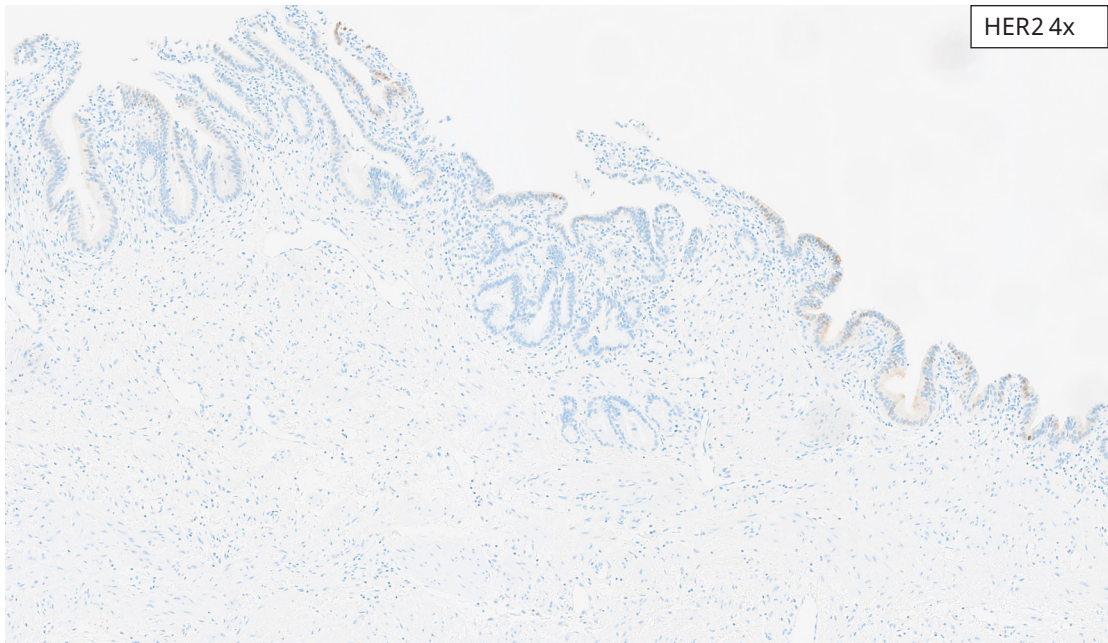
Non-neoplastic Hepatocytes - Cholangiocarcinoma Resection Case: Images demonstrate an intrahepatic cholangiocarcinoma without HER2 expression. The surrounding non-neoplastic hepatocytes, however, exhibit focal weak to moderate cytonuclear staining.



Non-neoplastic Hepatocytes - Cholangiocarcinoma Resection Case: Images at higher magnifications highlight the cytonuclear staining within hepatocytes and absence of HER2 staining within tumor cells (arrows).

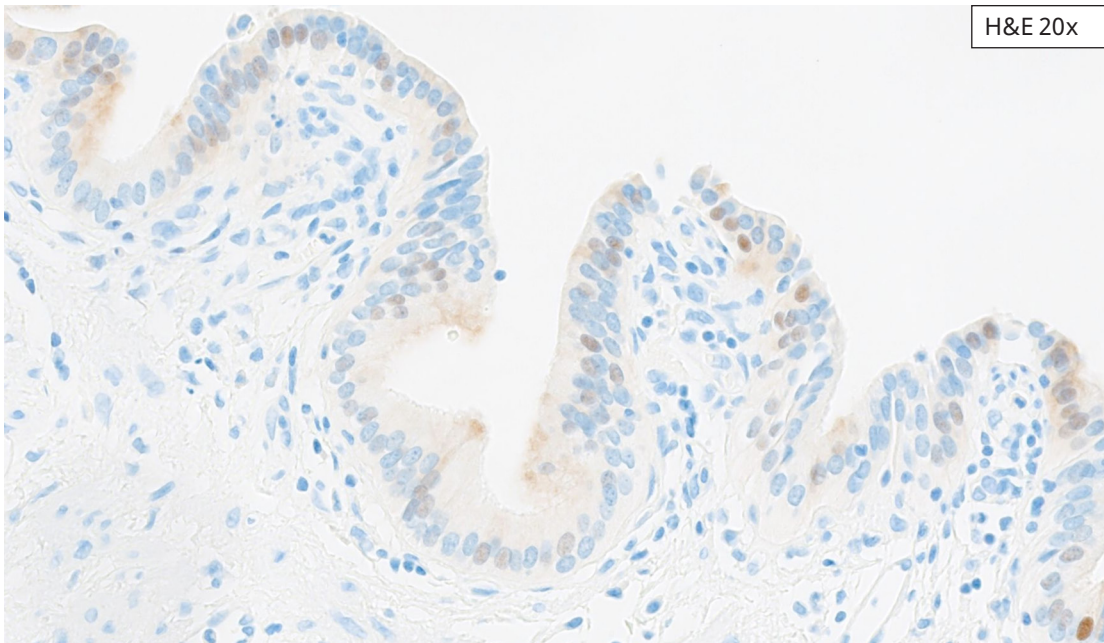
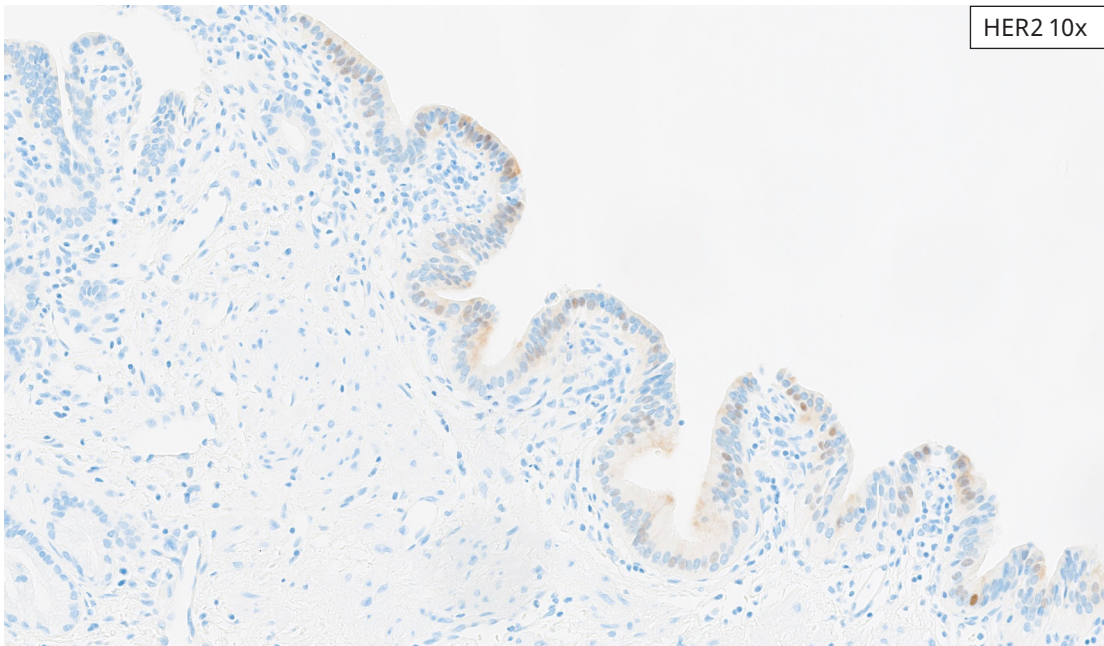


H&E 20x



HER2 4x

Non-neoplastic Epithelium - Cholangiocarcinoma Resection Case: Images show cytonuclear staining within non-neoplastic biliary epithelium.



Non-neoplastic Epithelium - Cholangiocarcinoma Resection Case: Images at higher magnification demonstrate weak to moderate cytonuclear staining within non-neoplastic biliary epithelium.

Summary: Important Points to Consider

- The HER2 IHC scoring algorithm in BTC tissues is different from that in breast carcinoma
- Lateral, basolateral and complete membrane staining all count towards IHC score
- Staining that is limited to the basal or apical region (without lateral membrane staining) should not be included in HER2 IHC score*
- Staining in the basal region of tumor cells may be more intense than in the corresponding lateral membranes; the intensity of the lateral membranes drives the IHC score*
- Scoring method for biopsies and resections are the same, but cut-points are different:
 - $\geq 10\%$ for resections
 - ≥ 5 contiguous tumor cells for biopsies
- Use of objective method:
 - 4x and 20x are most important objectives for decision-making
- 2+ cases: include cases with membrane staining of weak to moderate intensity, (not just moderate intensity)

*Rationale: Staining in the basal region cannot be confirmed either as specific for HER2, or specifically localized to the tumor cell membrane.

References

1. Akiyama T, Sudo C, Ogawara H, et al. The product of the human c-erbB-2 gene: a 185-kilodalton glycoprotein with tyrosine kinase activity. *Science*. 1986;232(4758):1644-1646.
2. Yan M, Parker BA, Schwab R, Kurzrock R. HER2 aberrations in cancer: implications for therapy. *Cancer Treat Rev*. 2014;40:770-780.
3. Yan M, Schwaederle M, Arguello D, Millis SZ, Gatalica Z, Kurzrock R. HER2 expression status in diverse cancers: review of results from 37,992 patients. *Cancer Metastasis Rev*. 2015;34:157-164.
4. Harder J, Ihorst G, Heinemann V, et al. Multicentre phase II trial of trastuzumab and capecitabine in patients with HER2 overexpressing metastatic pancreatic cancer. *Br J Cancer*. 2012;106:1033-1038.
5. Kawamoto T, Ishige K, Thomas M, et al. Overexpression and gene amplification of EGFR, HER2, and HER3 in biliary tract carcinomas, and the possibility for therapy with the HER2-targeting antibody pertuzumab. *J Gastroenterol*. 2015;50:467-79.
6. Fernandes VTO, Silva MJB, Begnami MD, Saito A. Prognosis of HER2 expression in cholangiocarcinoma when evaluated using gastric cancer methodology of immunohistochemistry. *ASCO 2015 Meeting Library*.
7. Puhalla H, Wrba F, Kandioler D, et al. Expression of p21Waf1/Cip1, p57Kip2 and HER2/neu in Patients with Gallbladder Cancer. *Anticancer Res*. 2007;27:1679-84.
8. Pignochino Y, Sarotto I, Peraldo-Neia C, et al. Targeting EGFR/HER2 pathways enhances the antiproliferative effect of gemcitabine in biliary tract and gallbladder carcinomas. *BMC Cancer*. 2010;10:631-44.
9. Roa I, de Toro G, Schalper K, de Aretxabala X, Churi C, Javle M. Overexpression of the HER2/neu Gene: A New Therapeutic Possibility for Patients With Advanced Gallbladder Cancer *Gastrointest. Cancer Res*. 2014;7:42-8.
10. Neyaz A, Husain N, Gupta S, et al. Investigation of targetable predictive and prognostic markers in gallbladder carcinoma *J Gastrointest. Oncol*. 2018;9:111-25.
11. Javle M, Churi C, Kang HC, et al. HER2/neu-directed therapy for biliary tract cancer. *J Hematol Oncol*. 2015;8:58.
12. Nam AR, Kim JW, Cha Y, et al. Therapeutic implication of HER2 in advanced biliary tract cancer *Oncotarget*. 2016;7:58007-21.
13. Yoshida H, Shimada K, Kosuge T, Hiraoka N. A significant subgroup of resectable gallbladder cancer patients has an HER2 positive status. *Virchows Arch*. 2016;468:431-9.
14. DePotter CR, Van Daele S, Van de Vijver MJ, et al. The expression of the neu oncogene product in breast lesions and in normal fetal and adult human tissues. *Histopathology*. 1989;15(4):351-362.
15. Press et al. Expression of the HER2/neu proto-oncogene in normal human adult and fetal tissues. *Oncogene* 5; 953-962, 1990.
16. Taylor et al. Cytoplasmic staining of c-erbB-2 is not associated with the presence of detectable c-erbB-2 mRNA in breast cancer specimens. *Int J Cancer* 76: 459-463, 1998.
17. Hoffman M, Stoss O, Shi D, et al. Assessment of a HER2 scoring system for gastric cancer: results from a validation study. *Histopath*. 2008;52:797-805.
18. Bartley AN, et al. HER2 Testing and Clinical Decision Making in Gastroesophageal Adenocarcinoma: Guideline From the College of American Pathologists, American Society for Clinical Pathology, and American Society of Clinical Oncology. *Arch Pathol Lab Med*. 2016 Dec;140(12):1345-1363. doi: 10.5858/arpa.2016-0331-CP. Epub 2016 Nov 14. PMID: 27841667.



Ventana Medical Systems, Inc.
1910 E. Innovation Park Drive
Tucson, AZ 85755
USA
+1 520 887 2155
+1 800 227 2155 (USA)



navifyportal.roche.com

© 2024 Ventana Medical Systems, Inc. All rights reserved.

VENTANA, BENCHMARK, CONFIRM, PATHWAY and ULTRAVIEW
are trademarks of Roche. All other product names and
trademarks are the property of their respective owners.

23356EN Rev A

2024-11-21

IVD

